

# Corona Virus Infectious Disease 19 (COVID-19) in Various Reviews

Huldani<sup>1\*</sup>, Herlina Uinarni<sup>2</sup>, Bayu Indra Sukmana<sup>3</sup>, Thomas Tommy<sup>4</sup>, Muhammad Fadli Said<sup>5</sup>, Edyson<sup>6</sup>, Amiruddin Eso<sup>7</sup>, RyantoKarobuana Sitepu<sup>8</sup>, EviMustikawati Arifin<sup>9</sup>, Ferra Olivia Mawu<sup>10</sup>, Arie Adrianus Polim<sup>11</sup>, IwanKurnia Effendi<sup>12</sup>, Yustinus Charles Ariestiyanto<sup>13</sup>, Hutasoit Charles Martamba<sup>14</sup>, Wafa Ahdiya<sup>15</sup>, Muhammad Hasan Ridhoni<sup>15</sup>, Harun Achmad<sup>16</sup>

\*<sup>1</sup>Department of Physiology and Immunology, Faculty of Medicine, Lambung Mangkurat University, Banjarmasin, South Kalimantan, Indonesia

<sup>1</sup>Department of Anatomy, School of Medicine and Health Sciences Atma Jaya Catholic University, Indonesia.

<sup>3</sup>Departement of Oral Radiology, Faculty of Dentistry, Lambung Mangkurat University, Banjarmasin, Indonesia.

<sup>4</sup>Department of Neurosurgery, Faculty of Medicine, Pelita Harapan University. Tangerang, Indonesia.

<sup>5</sup>Department of Neurosurgery, Faculty of Medicine, Hasanuddin University, Makassar, South Sulawesi, Indonesia.

<sup>6</sup>Department of Biochemistry, Faculty of Medicine, Lambung Mangkurat University, Banjarmasin, South Kalimantan, Indonesia.

<sup>7</sup>Department of Physiology, Faculty of Medicine, Halu Oleo University, Kendari, Southeast Sulawesi, Indonesia.

<sup>8</sup>Department of Surgery, Sub-Devison Digestive Surgery, Siloam Hospitals Lippo Cikarang, Indonesia.

<sup>9</sup>Department of Dermatology, Parikesit MA General Hospital, Kutai Kartanegara, East Kalimantan, Indonesia

<sup>10</sup>Department of Dermatology and Venerology, Faculty of Medicine, Sam Ratulangi University, Manado, Indonesia.

<sup>11</sup>Department of Obstetric and Gyneacology , School of Medicine and Health Science Atmajaya University, Jakarta, Indonesia.

<sup>12</sup>Department of Obstetric Gynaecology Oncology, Faculty of Medicine. Indonesia University, Jakarta, Indonesia.

<sup>13</sup>Department of Obstetric Gynecology, Mitra Medika Hospitals Pontianak, West Borneo, Indonesia

<sup>14</sup>Department of Urology, Siloam Hospital Kebon Jeruk, Jakarta, Indonesia.

<sup>15</sup>Student of Medical Education, Faculty of Medicine, Lambung Mangkurat University, Banjarmasin, South Kalimantan, Indonesia.

<sup>16</sup>Pediatric Dentistry Department, Faculty of Dentistry, Hasanuddin University, Makassar, South Sulawesi, Indonesia.

E-mail: [huldani@gmail.com](mailto:huldani@gmail.com)

Article History:

Submitted: 13.04.2020

Revised: 17.05.2020

Accepted: 24.06.2020

## ABSTRACT

The current COVID-19 outbreak was caused by a new coronavirus, SARS-CoV-2. It accesses host cells through the angiotensin-converting enzyme 2 (ACE2) protein, which is expressed by endothelial cells (EC) and very abundantly expressed in the lungs. SARS-CoV-2 uses a surface glycoprotein (peplomer) called a spike to access host cells and ACE2 has been revealed to be a co-receptor for coronavirus entry. The antigen presentation of SARS-CoV mainly depends on the MHC I molecule, but MHC II also contributes to the presentation. Based on the mechanism of a common acute viral infection, the antibody profile against the SARS-CoV virus contains characteristic pattern of IgM and IgG production. By the end of week 12, SARS-specific IgM antibodies disappear, whereas IgG antibodies can last in a longer period of time, which shows IgG antibodies can mainly hold a protective role, and SARS-specific IgG antibodies mainly are S-specific and N-specific antibodies. Clinical manifestations are not only found in mucosa in the airways but also in the cardiovascular system, kidneys, central nervous system, pregnancy, skin, oral cavity

and digestive system. The diagnose of clinical presentation of COVID-19 is mainly based on a history of epidemiology, clinical manifestations of pneumonia symptoms (for example, fever, dry cough, myalgia, and shortness of breath) and several additional examinations, include detection of nucleic acids, CT scanning, immune identification technology (POCT) ) IgM / IgG, related to enzymes, immunosorbent assay (ELISA) and blood culture.

**Keywords:** COVID-19, SARS-CoV, IgG, IgM

## Correspondence:

Huldani  
Department of Physiology and Immunology, Faculty of Medicine  
Lambung Mangkurat University  
Banjarmasin  
South Kalimantan, Indonesia  
E-mail: [huldani@gmail.com](mailto:huldani@gmail.com)

DOI: [10.31838/srp.2020.6.122](https://doi.org/10.31838/srp.2020.6.122)

©Advanced Scientific Research. All rights reserved

## INTRODUCTION

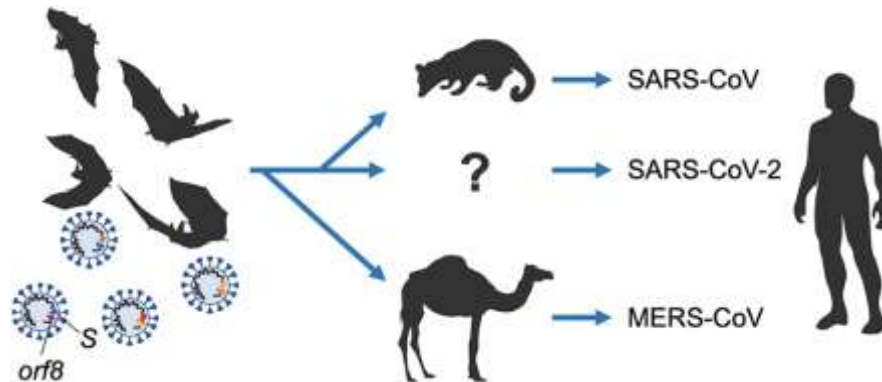
The corona virus infects many animal species such as humans, causing acute and chronic diseases. In 2002, SARS-CoV appeared in the human population in China, causing worldwide epidemics with severe morbidity and high mortality rates, especially in aged people.<sup>1</sup> Corona virus is an RNA virus that is present and widespread in humans, other mammals and birds and which cause respiratory, enteric, liver and neurological diseases. The corona virus forms an envelope structure on the outer surface of the virion and its morphology is round with a diameter of 100-160 nm,<sup>2</sup> and also contributes significantly to the spread of the virus in vivo and in the antagonist of the host cell response.<sup>1</sup> Their genome is positive-sense (+) single-stranded (ss) RNA and measuring 27-32 kb. Corona viruses have additional accessory genes in addition to genes for structural viruses of the virus.<sup>3</sup> There are six species of corona viruses that cause disease in humans. Four viruses, 229E, OC43, NL63, and

HKU1, usually cause the common cold symptoms in immunocompetent individuals. The other two types are SARS-CoV and MERS-CoV) originating from zoonoses and are associated with sometimes fatal diseases. SARS-CoV was the causative agent of a severe outbreak of acute respiratory syndrome in 2002 and 2003 in Guangdong Province, China. MERS-CoV is a pathogen responsible for the outbreak of severe respiratory disease in 2012 in the Middle East.<sup>2</sup>

The first case was identified in December 2019, a group of patients with pneumonia whose cause was unknown was associated with the seafood wholesale market located in Wuhan, China. The unknown Betacoronavirus was discovered through the application of unbiased sequencing in samples from patients with pneumonia. A new corona virus was isolated used human airway epithelial cells, named 2019-nCoV, which forms a clade in the sarbecovirus subgenus, the Orthocoronavirinae subfamily. 2019-nCoV is the seventh member of the corona virus family that infects humans.<sup>2</sup>

The current COVID-19 outbreak is caused by a new coronavirus, SARS-CoV-2, indicating that new pathogen variants will soon emerge from coronaviruses related to a

very diverse variety of severe acute respiratory syndromes (SARS-CoVs) originating from bats through high genetic recombination ability and close coexistence (Figure 1).<sup>3</sup>



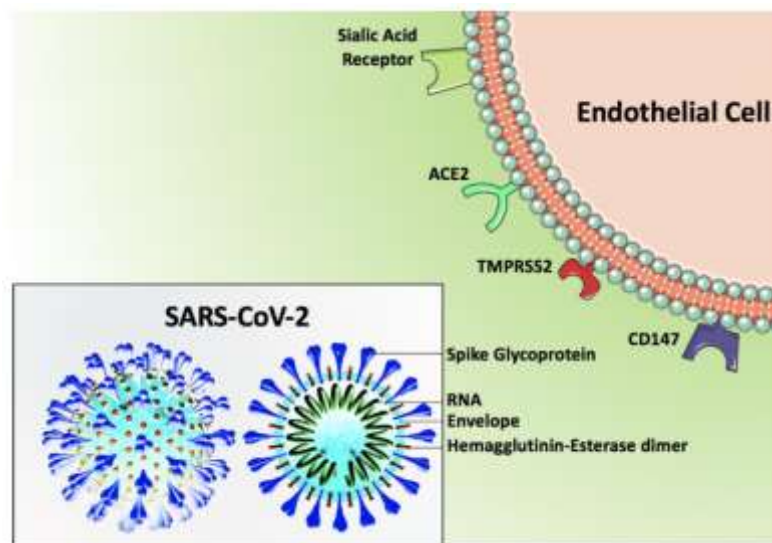
**Figure 1:** Presence of coronaviruses pathogenic for humans from ancestral bat viruses. Illustration of diversification of SARS-CoV, SARS-CoV-2, and MERS-CoV from ancestor viruses by possible genome recombinations. There are two major variable regions among viral genomes (S and orf8 genes). The variations occur mostly due to the high recombination potentials of the coronaviruses. (Source: Shun Adachi *et.al.*, 2020)

2019-nCoV compare to SARS-CoV is quite different when considered to a new betacoronavirus that infects humans. Eventhough phylogenetic analysis has revealed that bats may be the original host of this virus, but some animal sold in the seafood market in Wuhan may represent an intermediate host that facilitates the presence of the virus in humans. 2019-nCoV able to bind to ACE2 in humans based on its structural analysis.<sup>4</sup>

The symptoms appeared by patients affected by COVID-19 include coughing, fever, and shortness of breath. Besides, major symptoms such as high blood pressure, thrombosis, pulmonary embolism are usually observed in COVID-19 which indicate that the virus targets the endothelium.<sup>5</sup>

### PATHOPHYSIOLOGY AND PATHOGENESIS

Pathophysiology of this disease stated the reason of respiratory symptoms which is so common in patients, this occurs because the virus enters host cells through the angiotensin-converting enzyme 2 (ACE2) protein, which found very abundantly in the lungs. ACE2 is also expressed by endothelial cells (EC). SARS-CoV-2 uses a surface glycoprotein (peplomer) called a spike to access host cells and ACE2 has been shown to be a co-receptor for coronavirus entry. Thus, ACE2 density in each tissue may correlate with the severity of the disease in the tissue. Transmembrane serine protease 2 (TMPRSS2), sialic acid receptors, and the extracellular matrix metalloproteinase matrix inducer (CD147, also known as basigin) are receptors that mediate the entry of SARS-CoV<sup>5</sup>



**Figure 2:** Pathogenesis of COVID-19. The SARS-CoV-2 coronavirus enters host cells through the binding of its spike glycoprotein to angiotensin-converting enzyme 2 (ACE2), sialic acid receptor, transmembrane serine protease 2 (TMPRSS2), and extracellular matrix metalloproteinase inducer (CD147). (Source :Sardu, C *et.al.*, 2020)

Interestingly, ECs (Figure 2) expressed these four receptors. The most studied of these receptor because its genetic inactivation has been revealed to cause severe lung injury in mice exposed to H5N1, whereas administration of recombinant human ACE2 improves lung injury caused by the H5N1 virus in mice. ACE2 is debated among cardiologists, and there is concern that the medical management of hypertension, such as consuming the renin angiotensin-aldosterone system (RAAS) inhibitors, may contribute to poor health outcomes. In TMPRSS2 observations have been shown to bind to viral spike glycoprotein, a recent structural test showed that coronaviruses can bind to sialic acid receptors, CD147 has proven been very important for the access of cytomegalovirus into Ecs.<sup>5</sup>

After entering the cell through specific interactions of viral envelope glycoprotein (S) surges and cellular receptors, corona viruses replicate in the cytoplasm as other ssRNA (+) viruses. For alpha and beta-corona viruses, they come from highly metabolized mammals, such as bats and mice.<sup>3</sup>

Among the genes in the genome of interest, an evolutionary biologist tends to focus on genes that are functionally retained but differ in sequence. This is occur because the role of critical genes is conserved in various species, while developing rapidly, showing that divergent forces work on genes, for example, with joint evolution such as symbiosis, an evolutionary arms race, or others. From the CoV gene, this review focuses on the structural gene S as well as the orf3 / orf8 extra gene, each of which encodes the S protein and accessories. In addition, S gene and the upstream region of the orf8 gene are the most frequently observed hotspot for recombination. Based on the assumption, Orf8 from SARS-CoVis obtained from SARSr-CoV by recombination, and is chosen positively.<sup>3</sup>

The S protein contains receptor binding domains (RBD) that are important for infection, and the ORF3 / ORF8 protein functions as a virus-specific species, for example, by determining virulence (ORF8), anti-interferon activity (ORF3 / ORF8) or other. ORF3 / ORF8 differ between SARS-CoV and SARS-CoV-2, so they might contribute to differences in their virulence.<sup>6</sup>

Because RNA viruses are easily mutated and coronaviruses have high potential for recombination, it is easy to see traces of virus mutation and evolution, especially for SARS-CoV and MERS-CoV. RNA recombination by RNA polymerases that depend on low-fidelity RNA is widely observed and thought to form viruses today by reforming the genome or distributing functional modules.<sup>3</sup>

The evolution of coronavirus can be considered in Figure 1 which explain about viral gene, orf8 is known for the evolution of viruses and the increase in virulence observed during the slow onset of SARS. SARS-CoV uses ACE2 as a cellular receptor for infection, and MERS-CoV uses DPP4 as a receptor, for RBD in S. The introduction of receptors is crucial for the infection process for viruses. The difference in receptor use among coronaviruses is occurring because of the order / structure of their RBD. However, due to the general nature of RBD<sup>7</sup>, this can be a potential target for the development of new antiviral compounds and antibody therapies for this virus. Viruses have cleverly evolved to ward

off clinical strategies. For example, this strategy applies to WIV1 SARS-CoV strains but not to SHC014 and HKU3. We cannot include HKU3 for its truncated RBD form. For MERS-CoV, cells expressing DPP4-derived variants of bat species force the virus to accumulate mutations in the virus surge during travel, which results in increased viral entry with two amino acid mutation only. This phenomenon in virus evolution can be tested in either in vitro evolution or clinical medicine systems.<sup>3</sup>

To include the origins of new pathogens and the prevention of their transmission to humans and control the spread of viruses, both research on SARS-CoV, MERS-CoV, and SARS-CoV-2, and on their correlation to SARSr-CoVs and MERSr-CoVs in bats is recommended to track its ecology and evolution. Yunnan SARSr-CoVs may be the origin of SARS-CoVs (Figure 1), as symbionts, meanwhile domestication activities for mammals influence the acquisition of pathogenicity to humans. Both field research and experimental biology are needed to comprehend viruses simultaneously by predicting or preventing future outbreaks.<sup>3</sup>

#### Antigen Presentation in Coronavirus Infection

When a virus enters a cell, the antigen presentation cell (APC) releases antigen. It is a central part of the body's anti-viral immunity. Major histocompatibility complex (MHC; or human leukocyte antigen (HLA)) in humans) presents antigenic peptides and are then viral-specific cytotoxic T lymphocytes (CTL) recognized it. Therefore, understanding the antigen presentation of SARS-CoV-2 will help our understanding of the pathogenesis of COVID-19. The antigen presentation of SARS-CoV mainly depends on the MHC I molecule,<sup>8</sup> but MHC II also contributes to the presentation. Similar studies have shown many HLA polymorphisms correlate with SARS-CoV susceptibility, such as HLA-B \* 4601, HLA-B \* 0703, HLA-DR B1 \* 1202 and HLA-Cw \* 0801, while the HLA-DR0301 allele, HLA-Cw1502 and HLA-DR B1 \* 1202 and HLA-Cw \* 0801. -A \* 0201 is associated with protection from SARS infection.<sup>9</sup> MHC II molecules, such as HLA-DRB1 \* 11: 01 and HLA-DQB1 \* 02: 0, are associated with susceptibility to MERS-CoV infection, in MERS-CoV infection.<sup>10</sup> In addition, the MBL gene polymorphism (mannose binding lectin) is associated with antigen presentation associated with the risk of SARS-CoV infection.<sup>11</sup>

#### Humoral and Cellular Immunity

The antigen presentation then stimulates the body's humoral and cellular immunity. It is mediated by virus-specific B and T cells. Similar to a common acute viral infection, the antibody profile against the SARS-CoV virus has a characteristic pattern of IgM and IgG production. At the end of week 12, SARS-specific IgM antibodies disappear, whereas IgG antibodies can last for a long time, which shows IgG antibodies can mainly act as a protective agent,<sup>9</sup> and SARS-specific IgG antibodies mainly are S-specific and N-specific antibodies.<sup>12</sup> Compared to response humoral, there is more research on cellular immunity than coronavirus. Recent reports indicate the number of CD4 + and CD8 + T cells in peripheral blood infected by SARS-CoV-2 patients is

significantly decrease, while the status of increasing the activation, proven by the high proportion of HLA-DR (CD4 3.47%) and CD38 (CD8 39.4%) double-positive fraction.<sup>13</sup> At the same time, severe CD4 + T and CD8 + T decreases related to the acute phase response in patients with SARS-CoV. Even if there are no antigens, CD4 + and CD8 + memory T cells can last for four years in the individual recovering SARS-CoV and can carry out T cell proliferation, DTH response and IFN-production.<sup>9</sup>

Six years later SARS-CoV infection, T-cell memory responses specific to the SARS-CoV peptide library can still be recognized in 14 of 23 recovered SARS patients.<sup>14</sup> Specific CD8 + T cells also showed the same share on cleaning MERS-CoV in mice.<sup>15</sup> These results can provide valuable information for a rational vaccine design against SARS-CoV-2.

#### Coronavirus Avoidance of Host Immunity

For better survival in host cells, SARS-CoV and MERS-CoV apply several tactics to avoid the immune response. Evolutionally pattern recognition receptors (PRR) can recognize pathogen-related molecular patterns (PAMPs), a conserved microbial structures. Thus, SARS-CoV and MERS-CoV can induce the production of double-membrane vesicles that lack PRR and then replicate in these vesicles, thus avoiding detection of their dsRNA hosts.<sup>9</sup> IFN-I (IFN- $\alpha$  and IFN- $\beta$ ) forms a shield on SARS-CoV and MERS-CoV infections, but the IFN-I pathway is prevented in infected mice.<sup>16,17</sup> Additional protein 4a from MERS-CoV can stop IFN induction at the MDA5 activation level through direct interaction with double-stranded RNA. In addition, ORF4a, ORF4b, ORF5, and MERS-CoV membrane proteins inhibit nuclear transport from IFN 3 regulating factors (IRF3) and activation of  $\beta$  IFN promoters.<sup>9</sup> Coronaviruses can influence the presentation of antigens. It occurs when gene expression associated with antigen presentation is set down after the infection of MERS-CoV.<sup>18</sup> Thus, eradicating the immune avoidance of SARS-CoV-2 is very important in the curing and development of certain drugs.

### CLINICAL MANIFESTATION OF COVID-19

#### Manifestations in the Respiratory System

Pathological data on COVID-19 pneumonia from autopsy or biopsy is still lacking. Two patients who recently underwent pulmonary lobectomy for adenocarcinoma retrospectively were identified to have COVID-19 at the time of surgery. These two cases provide an important first opportunity to study the pathology of COVID-19. Pathological examination showed that the lungs of both patients showed edema, protein exudate, focal reactive hyperplasia of pneumocytes with evenly distributed inflammatory cellular infiltration, and large nucleated cells. Meanwhile hyaline membrane is not significant. Because both patients showed no symptoms of pneumonia at the time of surgery, this change was likely an early phase of the pathology of pulmonary pneumonia COVID-19.<sup>19</sup>

Sharon et.al 2020 reported similar cardiopulmonary invention in the initial series of autopsies in the United States, with causes of death due to SARS-CoV-2 infection.<sup>20</sup> The results of the Franck et.al 2020 study found that pulmonary

embolus patients were more often in critical care units than patients without pulmonary embolus (17 (74%) vs. 22 (29%) patients,  $p < 0.001$ ), requiring mechanical ventilation more frequently (15 (65%) compared to 19). (25%) patients,  $p < 0.001$ ) and had a longer delay of symptom onset for CT diagnosis of pulmonary embolism ( $12 \pm 6$  versus  $8 \pm 5$  days respectively,  $p < .001$ ). In a multivariable analysis, requirements for mechanical ventilation (OR = 3.8 IC95% [1.02-15],  $p = 0.049$ ) remained related to acute pulmonary embolus. Pulmonary embolus patients are more likely to require treatment in a critical care unit and need mechanical ventilation than those without pulmonary embolus.<sup>21</sup>

#### Manifestations in the Cardiovascular System

Heart risk factors and cardiovascular disease (CVD) patient potential in developing a high susceptibility to COVID-19 and lean to have more severe disease with poorer clinical outcomes.<sup>22,23</sup> In case reports of 138 COVID-19 patients treated at home 14.1% with early cardiovascular disease, and 31.1% with hypertension.<sup>24</sup> Other studies were smaller than 41 patients 14.6% with early cardiovascular disease, 14.6% with hypertension.<sup>25</sup> In the larger group than 416 patients, 30.5% with hypertension, 10.6% with coronary artery disease, and 5.3% with cardiovascular disease.<sup>26</sup> The prognostic significance of CVD was pretty much illustrated in a cohort of 191 patients, of which 30% had hypertension and constituted 48% of those who did not survive, while CVD was present at 8% which was 13% who did not survive.<sup>27</sup> A meta-analysis of six studies published from China, accommodate 1,527 patients with COVID-19, inform 9.7%, 16.4%, and 17.1% prevalence of diabetes, cardio-cerebrovascular disease, and hypertension. The study reveal case fatality rate (CFR) was 2.3% in the entire group but was significantly bigger (6%, 7.3%, and 10.5% respectively) in patients with hypertension, diabetes, and CVD.<sup>28</sup>

#### Manifestations of the Kidney

Coronavirus 2019 (COVID-19) mainly attacks the respiratory and immune systems, but an increase in creatinine values and acute kidney failure (ARF) is also experienced in some patients.<sup>1</sup> In studies of the clinical character of Coronavirus 2019-2020 in China, it was found that from 1099 COVID patients, 12 patients experienced an increase in creatinine value  $\geq 133 \mu\text{mol} / \text{L}$ , 6 patients in mild COVID cases and 6 patients in severe COVID cases. While cases of acute kidney failure were experienced by 6 patients in all cases, 1 in mild COVID cases and 5 in severe COVID cases.<sup>29</sup>

In theory, the incidence of ARF accompanied by proteinuria and hematuria can occur due to several factors:

1. Penetration of the COVID-19 virus into kidney tissue. With a light microscope found diffuse injury to the proximal tubules with loss of the brush border, non-isometric vacuolar degeneration, a clear smell of necrosis was also found.<sup>2</sup> With the electron microscope a group of corona virus particles was found with spikes that were clearly tubular epithelial and podocyte.
2. ACE2 receptor upregulation occurs in patients with COVID-19. In immunostaining, it was found that SARS-

CoV antibody nucleoprotein antibodies were present in the tubular epithelium.<sup>30</sup>

#### Manifestations in the Central Nervous System

Published reports of COVID-19 (SARS-CoV-2) infection stated that COVID-19 positive patients had non-specific neurological symptoms of fever, headache, nausea, vomitus, lethargy, gait disturbance, and malaise. These non-specific symptoms are related to prodromal syndrome of viral infection. Specific COVID-19 neurological symptoms ranges from anosmia,<sup>31,32</sup> seizure<sup>33</sup>, vision impairment, with cases of cerebral hemorrhage, cerebral infarction, and other neurological diseases.<sup>34</sup>

From the signs, symptoms, and cases evaluation, some hypothesis why COVID-19 infection has manifested neurologically has been proposed. First hypothesis, the manifestation of COVID-19 infection is associated with angiotensin-converting enzyme 2 (ACE2) receptors on human cell surfaces causing a reduced expression and function of ACE2 proteins, decreasing hypotensive effect of ACE inhibitor drug, causing uncontrolled hypertension, thus, increasing the risk of cerebral hemorrhage. There are also reports of glial cells,<sup>35</sup> and neurons expresses ACE2 receptors<sup>36,37</sup> which may cause direct virus-cell adhesion to the both said cells and causing symptoms.

Second hypothesis, using influenza A infection as a model, COVID-19 infection can pass into intracranial structures through olfactory route. This route is the primary mechanism of central nervous system invasion through retrograde transaxonal transport. Direct infection of olfactory ensheathing cells or channels in the cribriform plate can be the port of entry of virus into olfactory bulb then transported retrogradely into intracranial structures.<sup>38</sup> There are evidence of retrograde transport of drugs or molecules from nose to brain, through olfactory nerve endings, olfactory bulb and then transported intracranially. Moreover, there are connection from nasal cavity mucosa to the brain through trigeminal nerve endings via perivascular channels in the lamina propria or using intracellular/extracellular mechanism.<sup>39</sup> Other proposed mechanism of transport is that COVID-19 may reach the brainstem via a synapse-connected route from lung and airways.<sup>36,40</sup>

Third hypothesis, COVID-19 infection has direct effect to cerebral hemorrhage by disruption of blood coagulation cascade or homeostasis. There is some evidence that patients with COVID-19 had suffered from coagulopathy and prolonged prothrombin time and partial thromboplastin time. Contrary, COVID-19 patients may have increased D-dimer and fibrinogen, thus increasing risk of thromboembolic vascular events (cerebral arterial or venous infarction) warranting anticoagulant therapy and correlate with worse outcome.<sup>41,42,43</sup>

Furthermore, there are some publications report viral meningoencephalitis and tissue necrosis associated with COVID-19 infection. COVID-19 may cause acute necrotizing hemorrhagic encephalopathy.<sup>43</sup> Also, COVID 19 patients could presented with seizures and neck stiffness, signs of meningoencephalitis. This was evidenced by the detection of COVID-19 RNA sequences in the cerebrospinal fluid from a patient with meningoencephalitis.<sup>33</sup>

Further comprehensive studies regarding the manifestations of COVID-19 infection to central nervous system are needed to establish further understanding of this pandemic.

#### Manifestations in the Pregnancy

How covid 19 can affect both mother and fetus is not very clear and very little data is known. Pregnant women do not appear to be infected more often than the general population. Pregnancy itself generally changes the body's immune system and responds to viral infections, which sometimes cause more severe symptoms. The existence of vertical transmission from mother to fetus due to covid-19 infection has not been proven to date. A case report from China, there was no evidence of amniotic fluid, umbilical cord blood, neonatal swab, placental swab, and vaginal genital fluid and breast milk samples containing covid-19 from mothers infected with the virus and their babies were all tested with results negative.<sup>44,45,46,47</sup>

Individual responses to viral infections are very different for each pregnant woman to different viruses. In the type of coronavirus infection it seems that pregnant women will be more increased at the end of the pregnancy trimester. One study showed an increased risk of premature birth in women with maternal indications after 28 weeks of pregnancy.<sup>48</sup> Pregnancy alone will cause a hypercoagulable state<sup>49</sup> and evidence says pregnant women infected with covid-19 who are hospitalized with a hypercoagulable condition, due to covid-19 infection strongly associated with increased risk of venous thromboembolism<sup>50</sup> in mothers, therefore it is important to reduce mobility with independent isolation at home or hospital admission.

According to the final WHO-China joint Mission on Covid 19 study published in February 2020, noted that the H1N1<sup>51</sup> influenza virus, pregnant women did not appear to have a high risk of becoming heavier than the general population. From a study of 147 pregnant women (64 positive confirmed, 82 suspects and 1 asymptomatic), 8% had severe disease and 1% became critical. From a systematic review of 108 pregnant women found that 3% of pregnant women need ICU treatment for covid-19 infections, but 2 of the 3 cases were women with comorbidities with diabetes mellitus that were not controlled by obesity, the second with chronic hypertension comorbid, diabetes mellitus and obesity. A recent systematic review looking for maternal and perinatal outcomes with covid-19 found most studies did not release any adverse events from perinatal outcomes. However, from a review by the study of Zhu et al. Reported that there were 1 neonatal deaths from 6 neonates who entered the NICU, 6 out of 10 neonates were born premature.<sup>52</sup>

Therefore, pregnant women with covid-19 infection must undergo a PCR test swab, therefore RCOG recommends that pregnant women should do social distancing by doing telehealth medicine and only emergency patients can come to the hospital so they can reduce the density by 50 -80% of patients in the hospital and the need for initial knowledge and awareness of the staff of employees in the hospital so as to reduce about 10% of unknown cases.<sup>53</sup>

Manifestations in the Oral Cavity

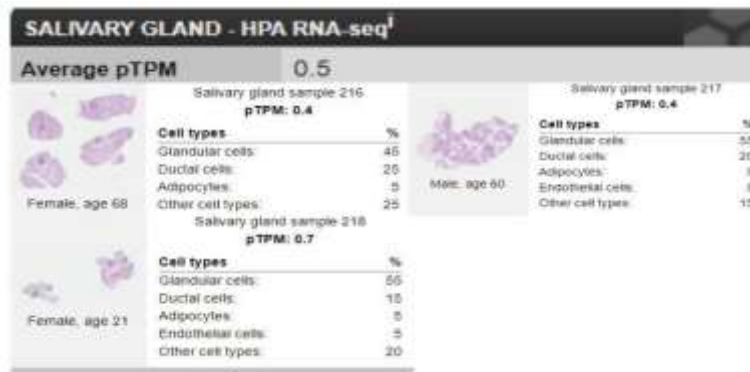
COVID-19 transmission can occur through droplets and aerosols which often occur in dental clinic activities. Further research is needed to promote COVID-19 in oral fluids and its effects on transmission of this virus. This research is very important to enhance an effective debate strategy, specifically for dentists and other health professionals who carry out clinical procedures that produce aerosols.<sup>54</sup>

Droplets can come from the nasopharynx or oropharynx and are associated with saliva. In people who have been infected with the COVID-19 virus through droplets can cause other people involved can also fight. and cause long-distance transmission with virus droplets that will be retained in the air. In this context, health workers, such as dentists, might handle direct treatment in patients who have difficulty COVID-19 but this person has not been diagnosed, or in people who are considered surveillance.<sup>55,56</sup> Patients who replace COVID-19 can change symptoms that appear as

symptoms before transmission can occur before COVID-19 symptoms appear. A study in China showed that 29% of 138 patients suffering from COVID-19 were health care workers.<sup>57</sup> Inhalation of airborne particles and aerosols produced during dental clinical procedures in patients fighting COVID-19 can make dentists highly vulnerable to the COVID-19 virus directly. Therefore, it is very important for dentists to refine strategies to prevent COVID-19 infection by replacing patient placement, hand hygiene, wearing all personal protective equipment (PPE), and being careful in carrying out aerosol-producing procedures.<sup>58</sup>

There are three pathways for COVID-19 to enter saliva: First through the Upper and Lower respiratory tract which will enter the oral cavity. Both COVID-19 in the blood can be accessed by the oral cavity through cervical fluid, or outside the oral cavity which contains protein and originates from the extracellular matrix of blood serum, and the last is COVID-19 which is inserted through saliva through the use of saliva mayor and minor.<sup>59</sup>

Table 1: Data from the HPA Dataset shows mRNA expression from the ACE2 gene detected in normal salivary gland tissue (pTPM mean: 0.5), with the highest expression level observed in gland cells

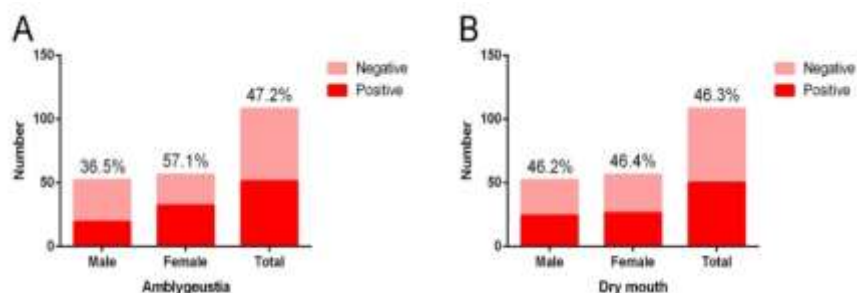


Among the 14 oral manifestations of patients infected with COVID-19, patients who experienced symptoms of amblygeusia with an overall value of 47.2% (Men 36.5%, Women 57.1%). Dry mouth / Xerostomia with an overall

value of 46.3% (Men 46.2%, Women 46.4%). Oral inflammation occurs in 11.1% (13.5% in men, 8.9% in women). One female patient had enlarged lymph nodes in the submandibular area.<sup>60</sup>

Table 2: Percentage of oral manifestations in male and female patients infected with COVID-19

	Male (N=52)	Female (N=55*)	Total (N=107*)
<b>Age (M±SD)</b>	51.1 (15.26)	52.9 (17.28)	52.0 (16.28)
<b>Oral-related symptoms [n (%)]</b>			
	Male (N=52)	Female (N=56)	Total (N=108)
<b>Initial symptoms [n (%)]</b>			
Amblygeusia	19 (36.5)	32 (57.1)	51 (47.2)
Dry mouth	24 (46.2)	26 (46.4)	50 (46.3)
Dryness and inflammation of mouth	7 (13.5)	5 (8.9)	12 (11.1)
Enlargement of lymph nodes in the submandibular regions	0	1 (1.8)	1 (0.9)



Graph 1: The highest percentage of oral manifestations in patients infected with COVID-19

In the oral cavity the percentage of manifestations of amblygeusia was 47.2%, 36.5% in men, 57.1% in women and xerostomia was 46.3% (46.2% in men, 46.4% in women).

#### Manifestations of the Gastro-Intestinal System

In an initial report from Wuhan, 2-10% of patients with COVID-19 had gastro-intestinal symptoms such as diarrhea, abdominal pain and vomiting. Abdominal pain is reported more frequently in patients with ICU care compared with those not requiring ICU care, 10% of patients get diarrhea and nausea 1-2 days before symptoms develop into body heat and respiratory symptoms.<sup>61,62</sup>

Intestinal involvement and diarrhea associated with respiratory symptoms are a common clinical picture of viral infections belonging to the corona virus family. Liquid diarrhea without blood and mucus is a frequent symptom (20.3%), diarrhea with febrile combination (5.8%). 38.4% sufferers have diarrhea for 3 weeks. SARS-CoV can be identified in terminal ileum and colon biopsy and RT-PCR examination of fecal samples, and can be detected up to 10 weeks after symptom onset.<sup>63,64</sup>

Several studies provide evidence that corona virus can cause gastrointestinal tract infections since the discovery of ACE2 and TMPRSS2 together in enterocytes, as well as in the lungs and esophagus. The specific mechanism of diarrhea pathogenesis is not yet fully known, but it is suspected that SARS-CoV-2 causes disruption of ACE2 function and produces diarrhea. viral infection causes changes in intestinal permeability that result in malabsorption of enterocytes. In addition ACE2 is involved in absorption of the amino acid diet, regulation of antimicrobial peptide expression and promoting intestinal microbiome homeostasis.<sup>61,62</sup>

Laboratory stools found 6.9% of patients had faecal abnormalities, with 5.2% leukocytes and 1.7% faint blood but

no red blood cells were found, this is consistent with the character of viral diarrhea.<sup>64</sup>

The SARS-CoV2 enteric manifestation is an important diagnostic challenge for clinicians when dealing with COVID-19 patients who have mild symptoms at the onset of their disease as well as has significant potential for viral transmission through the faecal. Reported in a recent study doing intracellular nucleocapsid viral protein and ACE2 protein expression in humans in gastric, duodenal and rectal epithelial cells, providing understanding that ACE2 receptors can become entry points for the SARS-CoV-2 virus in the intestinal tract.<sup>63</sup>

#### Skin Manifestations due to COVID-19 and PPE use

COVID-19 infection which affect skin focus on the effects of hyperhydration PPE, friction, epidermal breakdown, and contact reactions, all of which can exacerbate existing skin diseases. The most commonly used skin changes due to prolonged use of PPE (figure 3) are erythema, papules, maceration, and scaling which appear on the skin. Causes include burning, itching, and stinging. This finding supports the use of PPE in 97.0% of 542 frontline health workers (HCW). Long-term use of protective gloves causes occlusion and hyper-hydration of the epidermis which can be used clinically as maceration and erosion (4), which may be needed in the development of contact dermatitis. Washing hands with excessive detergent / can damage the hydro-lipid layer on the surface of the skin and may also affect irritation on skin and also the appearance of contact dermatitis (figure 4). Two-thirds of health care workers will wash their hands more than 10 times a day, meanwhile only 22% use protective skin creams.<sup>65</sup>

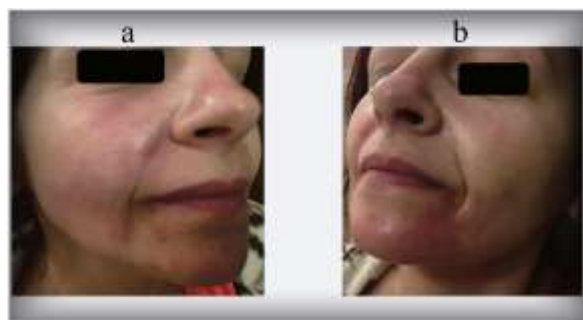

Figure 3: The appearance of facial burning, itching, erythema and papules in 42-years-old female patients who disinfected her face with 60% ethanol 5 times daily and also wear protective facial mask for 6 hours a day. (Source: Darlenski, 2020)

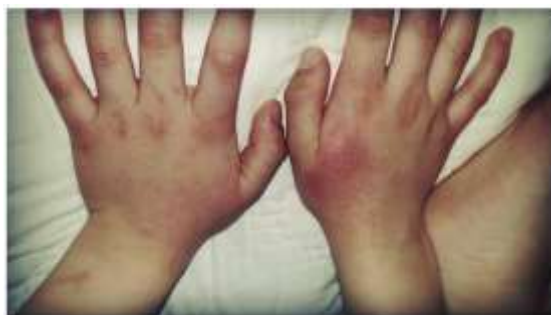

Figure 4: Arising of hand dermatitis because of excessive hand washing as a preventive action in COVID-19 transmission. (Source: Darlenski, 2020)

The appearance of skin rash with petechiae has also been indicated as a possible early onset of COVID-19 disease, and acute hemorrhagic edema in infants associated with coronavirus NL63. There is one case of COVID-19 infection that shows skin disease. This case occurred in a 28-year-old woman with no previous medical history, initially had a dry cough, nasal congestion, fatigue, myalgia and arthralgia without fever. He was positive for corona virus. Thirteen days later the patient began to notice pruritus lesions on both heels. Confluent yellowish erythematous papules were

observed in both heels (Figure 5), without lesions on other parts of the skin. The patient did not wear tight socks, shoes or local pressure that could explain the distribution of the lesion. Application of local corticosteroids is recommended. Because of this, three days later, the lesions persisted and became hardened erythematous plaques and pruritus (Figure 6). At this condition, urticaria, urticaria vasculitis, idiopathic plantar hydradenitis and neutrophilic dermatosis are considered in the differential diagnosis. Thus, a biopsy was not conducted.<sup>66</sup>

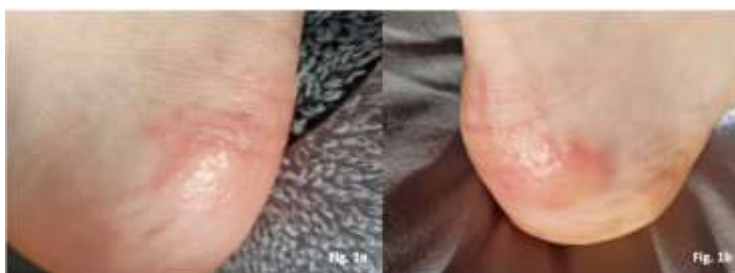

Figure 5: Dried erythematous-yellowish papules in right (1a) and left heel (1b). (Source : Andrea et.al, 2020)

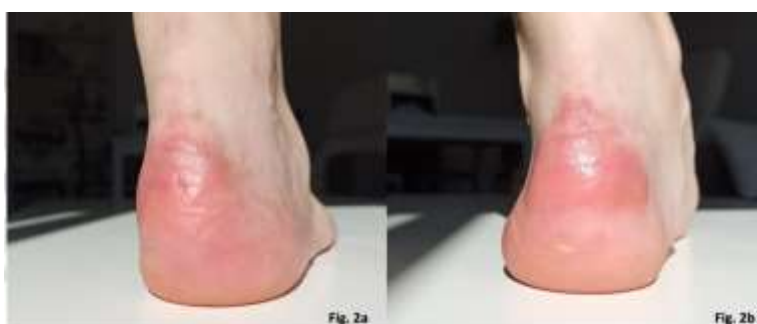

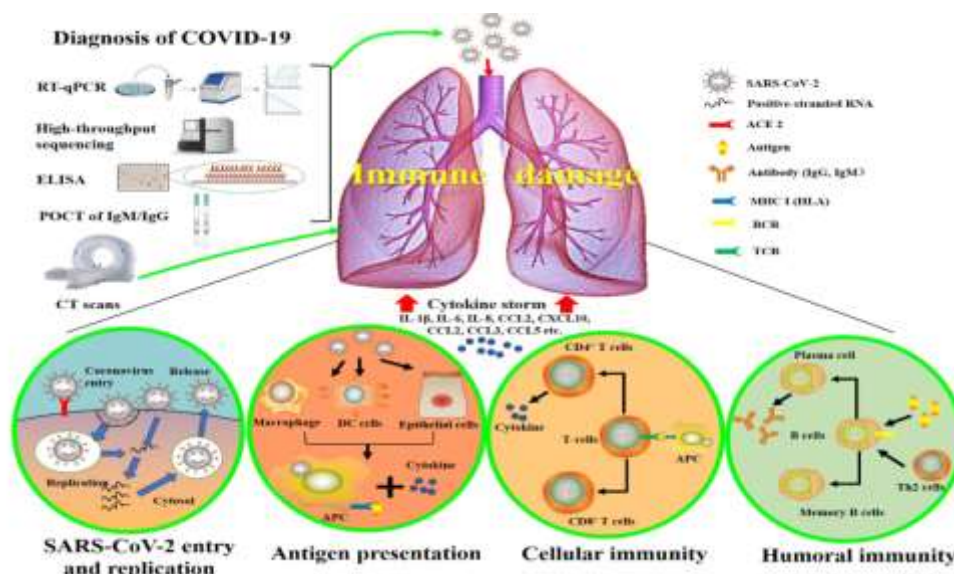
Figure 6: Intensely pruritic erythematous compact plaques in right (1a) and left heel (1b) three days later despite topical corticosteroids. (Source :Estebanez et.al, 2020)

### COVID-19 DIAGNOSIS

The clinical diagnosis of COVID-19 is mainly based on a history of epidemiology, clinical manifestations and some additional examinations, such as detection of nucleic acids, CT scans, IgM / IgG immune identification technology (POCT), related to enzymes. immunosorbent assay (ELISA)

and blood culture. Thus, clinical symptoms as well as indications of patients infected with SARS-CoV-2 are very unusual, such as respiratory symptoms, coughing, fever, dyspnea, and viral pneumonia. Furthermore, additional tests are needed for the diagnosis of COVID-19, as well as epidemiological history of the patients.<sup>9</sup>





(Source: Xiaowei Li *et al.*, 2020)

Figure 7: COVID-19 Diagnosis

#### Technology for detecting Nucleic acid

Technology applies to detect two nucleic acid commonly used for SARS-CoV-2 are real-time quantitative polymerase chain reactions (RT-qPCR) and high throughput sequencing. The authoritative identification method for SARS-CoV-2 is viral blood culture and high throughput sequencing of the entire genome.<sup>9</sup> Meanwhile, the application of high throughput sequencing technology in clinical diagnosis is limited due to equipment dependence and expensive costs. Thus, RT-qPCR is the most general, effective and easy method for detecting pathogenic viruses in respiratory and blood secretion.<sup>67</sup> RT-qPCR has several weaknesses, including certain biological safety hazards brought by patient retention and sample operations, nucleic acid detection operations complicated, and long waiting times for the results.

#### CT scans methods and others

COVID-19 is diagnosed using RT-qPCR which will provide specific result, but, the negative numbers cannot be neglected because of the severe outcome of the missed diagnosis. Numerous doctors who propose CT scanning should be one of the additional diagnostic methods needed because it is more accurate. Individuals with high clinical suspicion of SARS-CoV-2 infection with negative RT-qPCR screening, a combination of repeated RT-qPCR tests and chest CT scans may be useful. Particularly high-resolution CT (HRCT) for the chest is very important for initial diagnosis and evaluation of the disease severity of patients infected SARS-CoV-2.<sup>68</sup> Several research have observed chest CT images of patients diagnosed with SARS-CoV-2.<sup>69,70</sup> Typical CT images showing ground-glass Bilateral pulmonary parenchyma and consolidated pulmonary opacification, occasionally with spherical morphology and peripheral pulmonary distribution. Lung infection with peripheral dominance is also seen in patients with SARS-CoV and MERS-CoV infections, and chest CT shows that the disease develops with turbidity and soil glass consolidation, which is the same as

SARS-CoV-2.9 infection. Based on these findings, CT scan has a value clinical diagnosis of COVID-19 is great, especially in areas of high prevalence of SARS-CoV-2 infection. Furthermore, CT scan also has some disadvantages, such as the incomparability of other viral pneumonia and abnormal CT imaging hysteresis.

Given the shortcomings of nucleic acid detection and CT scanning currently used for COVID-19 diagnosis, clinical laboratories must implement several immunological detection devices that focus on viral antigens or antibodies as soon as possible. At present, POCT of IgM / IgG and ELISA kits for SARS-CoV-2 have been promoted and tested previously by several companies and have shown greater detection rates than nucleic acid detection, but no products or articles have been published yet. Sensitivity of SARS-CoV-based ELISA ELISA (94.7%) was significantly greater than SARS-CoV-based ELISA IgISA (58.9%),<sup>71</sup> but the sensitivity of SARS-CoV-2 IgG / IgM SARS remained to be researched. Therefore, developing additional sensitive and particular additional methods is needed and important for the diagnosis of COVID-19.

#### Imaging In Adult Patiens With Covid 19

Fixed test for SARS-CoV-2 is the real-time reverse transcriptase-polymerase chain reaction (RT-PCR) test. This method is known to be highly specific, but sensitivity is as low as 60-70%<sup>32</sup> and as high as 95-97%.<sup>72</sup> Sometimes, the results of the PCR test may not available, delayed or take several hours.

The diagnosis of COVID-19 is thought to be based on symptoms of pneumonia (for example, fever, dry cough, myalgia, and shortness of breath) and a recent travel history for exposure in known patients.<sup>73</sup> Clinicians have to observe the symptoms, which are very unspecific. Meanwhile, there are some symptoms that complicate suspicion. Analytical alterations such as lymphopenia, elevation of C-reactive protein (CRP) and transaminases or lactate dehydrogenase augment the degree of suspicion. In emergency department

(ED), the chest X-ray can be a discriminating element. Sometime, the lack or presence of pathological characteristics on chest X-ray is applying to send the patient home or keep him/her under observation but if the clinical suspicion is elevate and the PCR or/and chest X-ray is normal, a chest CT is needed.

Conducting differentiation in the beginning, between ED patients with and without corona virus disease (COVID-19) is very crucial. Chest CT scan may be beneficial in early diagnosing of COVID-19. The chest CT in symptomatic ED patients is accurate, but applied as a single diagnostic test, CT scan cannot effectively diagnose or exclude COVID-19.<sup>74</sup> Determining COVID-19 status at the beginning is crucial for disease treatment to reduce morbidity and mortality and minimize disease transmission. Contrast to RT-PCR, chest CT imaging is more reliable, practical and rapid method to diagnose and determine COVID-19, particularly in the epidemic area.<sup>75</sup>

A report of 121 patients with confirmed COVID-19 in relation to the time between symptom onset and the first CT scan. CT results were more frequent, including consolidation, bilateral and peripheral disease, linear opacities, “crazy-paving” pattern and the “reverse halo” sign. Bilateral lung picture was observed in 28% early patients 76% intermediate patients and 88% late patients.<sup>76</sup>

The typical radiological findings that make strongly suspect that is COVID-19 infection. The specific CXR finding classification is applied to denote the imaging pattern most suggestive of COVID-19 pneumonia; such as bilateral peripheral and/or subpleural ground-glass opacities (GGO) and/or consolidation. (Figure 8) The typical CT finding are the CCO areas, which, even in the initial stages on CT-scan, affect both lungs, in particular the lower lobes, and specifically the posterior segments, with a fundamentally peripheral and subpleural distribution. (figure 9, 10 and 11)

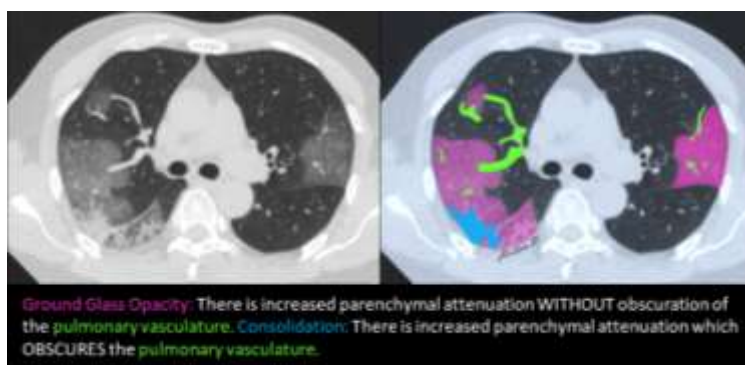


Figure 8: An axial-CT-scan Covid-19 patient, subpleural ground-glass opacities (GGO) and consolidation.

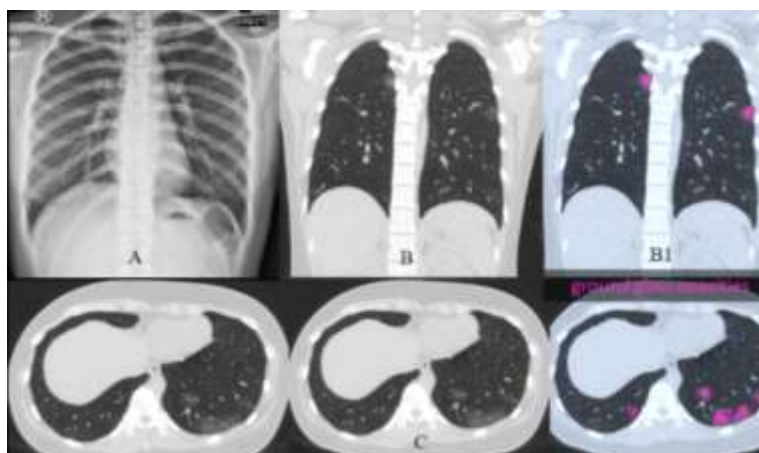


Figure 9: A. A chest X-ray and an coronal (B), axial (C) CT image in a 25-year-female mild common type Covid-19 patient ( atypical symptom/sinusitis onset, 3 days from normal sinus paranasal X-ray to chest X-ray and CT scan) shows multiple GGO in peripheral distribution both lungs.

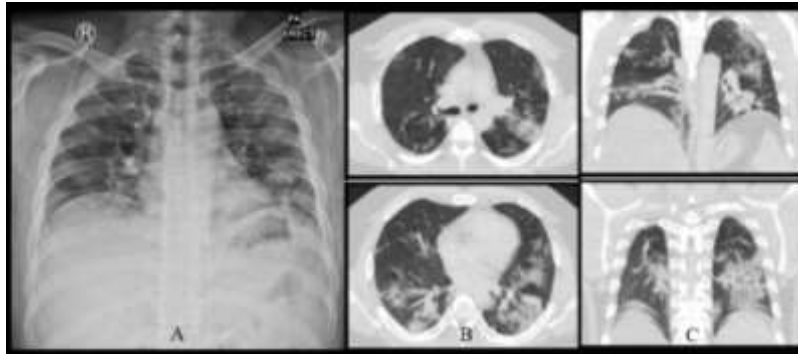


Figure 10: A. A chest X-ray and axial (B), coronal (C) CT picture in a 37-year-old male moderate common type patient (5 days from symptom onset to chest X-ray and CT scan) reveals multiple GGO in both lungs.

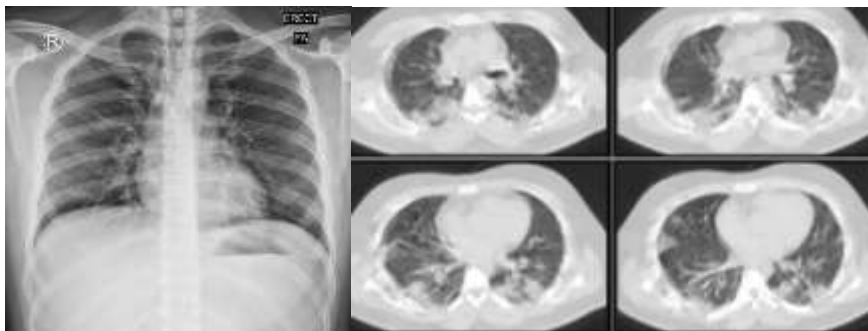


Figure 11: A. A chest X-ray and an axial CT image in a 27-year-old male moderate common type patient (5 days from symptom onset to chest X-ray and CT scan) reveals multiple GGO in both lungs.

Four stages on temporal CT changes Covid-19 have been described :<sup>77</sup> 1. Early/initial stage (0-4 days): normal CT or GGO only, up to half of patients have normal CT scans within two days of symptom onset, 2. Progressive stage (5-8 days): increased GGO and crazy paving appearance, 3. Peak stage (9-13 days): consolidation, 4. Absorption stage (>14 days):

with an improvement in the disease course, "fibrous stripes"/linear opacities appear and the abnormalities resolve at one month and beyond. (Figure 5) Chest CT is applied also to determine the severity of lung involvement in COVID-19 pneumonia (Figure 12)

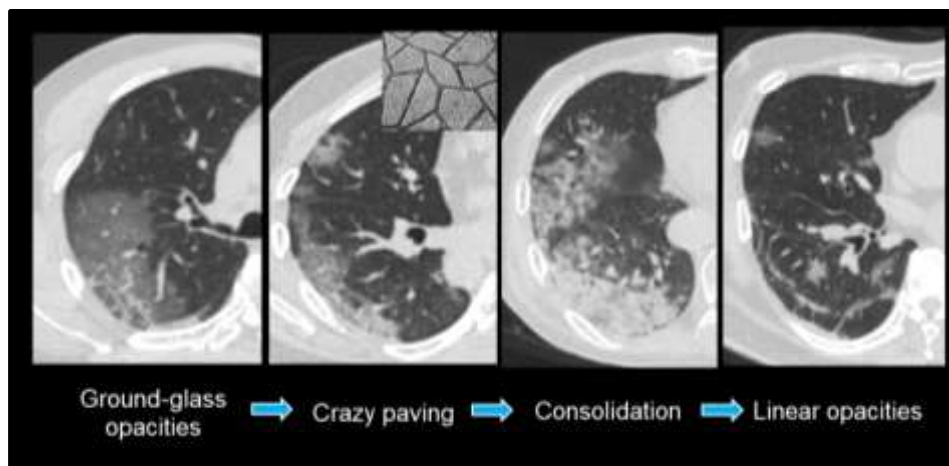
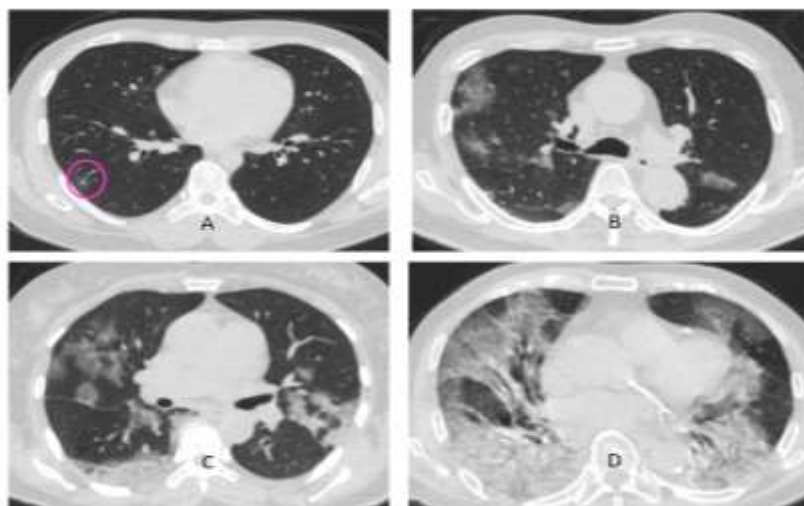


Figure 12: Temporal CT changes. Ground Glass Opacity, Crazy paving (the combination of septal thickening and alveolar ground-glass opacity creates a pattern that mimics paving), consolidation and linear opacities.



**Figure 13:** CT image of coronavirus disease-2019 by disease severity. A. An axial CT image in a 26-year-male mild type patient (3 days from symptom onset to CT scan) GGO in right lung. B. An axial CT image in a 69-year-male common type patient (7 days from symptom onset to CT scan) shows multiple GGO in both lungs. C. An axial CT image in a 55-year-female severe type patient reveals extensive GGO and pulmonary consolidation. D. An axial CT image in an 83-year-male critical type patient (7 days from symptom onset to CT scan) reveals wide ground-glass opacities in multiple lobes, relative formatting "white lung".

Although chest imaging especially CT scans plays a crucial role in determining the disease extent and follow-up. Besides, the features that are stated to be most characteristic of COVID-19 pneumonia (i.e., peripheral, bilateral ground glass opacities that are predominantly found in the lower lobes) can be observed in a large number of other conditions, including other infectious and noninfectious conditions. The sensitivity of CT varies widely, and none of the research sufficiently evaluate the application of CT in a representative screening population.<sup>73</sup>

Some authors are mindful support CT as a sufficient replacement assay because its real sensitivity is unknown (and is unlikely to be of value given the known existence of normal CT findings in patients with the disease) and because CT findings lack specificity. On 16 March 2020, an American-Singaporean panel reported that CT findings were not part of the diagnostic criteria for COVID-19. Imaging only for those COVID-19 patients where imaging will impact management.<sup>72</sup>

## CONCLUSION

Corona virus infection called COVID-19 (Corona Virus Disease 2019) was appeared in Wuhan city, China. It was discovered in late December 2019. It has spread to almost all countries in the world and transmitted rapidly among humans, just in a few months. The characteristics of COVID-19 viruses are different from those in SARS and MERS, including the speed of spread and the severity of symptoms. The effect of corona virus will appeared when someone is infected, but will be more harmful and even fatal if it induced elderly people, pregnant women, people who have certain diseases, smokers, or people whose immune systems are weak.

## REFERENCES

1. Weiss, SR; Leibowitz. Coronavirus Pathogenesis. *Advances In Virus Research*. Book Series: *Advances in Virus Research*. 2012; 81 : 85-164. DOI: 10.1016/B978-0-12-385885-6.00009-2
2. Zhu N, Zhang D, Wang W, Li X, Yang B, Song J, Zhao X, Huang B, Shi W, Lu R, Niu P, Zhan F, Ma X, Wang D, Xu W, Wu G, Gao GF, Tan W; China Novel Coronavirus Investigating and Research Team. A Novel Coronavirus from Patients with Pneumonia in China, 2019. *N Engl J Med*. 2020 Feb 20;382(8):727-733. doi: 10.1056/NEJMoa2001017.
3. Shun Adachi, TakaakiKoma, Naoya Doi, Masako Nomaguchi, and Akio Adachi. Commentary: Origin and evolution of pathogenic coronaviruses. *Front. Immunol.*, 21 April 2020 | <https://doi.org/10.3389/fimmu.2020.00811>
4. Lu R, Zhao X, Li J, Niu P, Yang B, Wu H, Wang W, Song H, Huang B, Zhu N, Bi Y, Ma X, Zhan F, Wang L, Hu T, Zhou H, Hu Z, Zhou W, Zhao L, Chen J, Meng Y, Wang J, Lin Y, Yuan J, Xie Z, Ma J, Liu WJ, Wang D, Xu W, Holmes EC, Gao GF, Wu G, Chen W, Shi W, Tan W. Genomic characterisation and epidemiology of 2019 novel coronavirus: implications for virus origins and receptor binding. *Lancet*. 2020 Feb 22;395(10224):565-574. doi: 10.1016/S0140-6736(20)30251-8. Epub 2020 Jan 30.
5. Sardu, C.; Gambardella, J.; Morelli, M.B.; Wang, X.; Marfella, R.; Santulli, G. Is COVID-19 an Endothelial Disease? *Clinical and Basic Evidence*. Preprints 2020, 2020040204 (doi: 10.20944/preprints202004.0204.v1).
6. Yuen K-S, Ye Z-W, Fung S-Y, Chan C-P, Jin D-Y. SARS-CoV-2 and COVID-19: the most important research questions. *Cell Biosci.* (2020) 10:40. doi: 10.1186/s13578-020-00404-4

7. Letko M, Marzi A, Munster V. Functional assessment of cell entry and receptor usage for SARS-CoV-2 and other lineage B betacoronaviruses. *Nat Microbiol.* (2020) 5:562–9. doi: 10.1038/s41564-020-0688-y
8. J. Liu, P. Wu, F. Gao, et al., Novel immunodominant peptide presentation strategy: a featured HLA-A\*2402-restricted cytotoxic T-lymphocyte epitope stabilized by intrachain hydrogen bonds from severe acute respiratory syndrome coronavirus nucleocapsid protein, *J. Virol.* 84 (2010) 11849-11857. <https://doi.org/10.1128/JVI.01464-10>
9. Xiaowei Li, ManmanGeng, Yizhao Peng, Liesu Meng, Shemin Lu. Antigen presentation in coronavirus infection. Molecular immune pathogenesis and diagnosis of COVID-19. *Journal of Pharmaceutical Analysis* (2020), doi: <https://doi.org/10.1016/j.jpha.2020.03.001>
10. A. H. Hajeer, H. Balkhy, S. Johani, et al., Association of human leukocyte antigen class II alleles with severe Middle East respiratory syndrome-coronavirus infection, *Ann. Thorac. Med.* 11 (2016) 211-213. <https://doi.org/10.4103/1817-1737.185756>
11. Scollo, S., La Camera, G., Neri, S., Grasso, C., Cubisino, R., Bonsignore, C., La Rosa, V., Astuto, M. Acquired angioedema of the glottis, larynx and neck in a patient affected by SLE: Case report (2018) *European Journal of Molecular and Clinical Medicine*, 5, pp. 16-19. DOI: 10.5334/ejmcm.247
12. X. Tu, W. P. Chong, Y. Zhai, et al., Functional polymorphisms of the CCL2 and MBL genes cumulatively increase susceptibility to severe acute respiratory syndrome coronavirus infection, *J. Infect.* 71 (2015) 101-109. <https://doi.org/10.1016/j.jinf.2015.03.006>
13. E. de Wit, N. van Doremalen, D. Falzarano, et al., SARS and MERS: recent insights into emerging coronaviruses, *Nat. Rev. Microbiol.* 14 (2016) 523-534. <https://doi.org/10.1038/nrmicro.2016.81>
14. Z. Xu, L. Shi, Y. Wang, et al., Pathological findings of COVID-19 associated with acute respiratory distress syndrome, *Lancet Resp. Med.* (2020). [https://doi.org/https://doi.org/10.1016/S2213-2600\(20\)30076-X](https://doi.org/https://doi.org/10.1016/S2213-2600(20)30076-X)
15. F. Tang, Y. Quan, Z. T. Xin, et al., Lack of peripheral memory B cell responses in recovered patients with severe acute respiratory syndrome: a six-year follow-up study, *J. Immunol.* 186 (2011) 7264-7268. <https://doi.org/10.4049/jimmunol.0903490>
16. J. Zhao, K. Li, C. Wohlford-Lenane, et al., Rapid generation of a mouse model for Middle East respiratory syndrome, *Proc. Natl. Acad. Sci. U. S. A.* 111 (2014) 4970-4975. <https://doi.org/10.1073/pnas.1323279111>
17. R. Channappanavar, A. R. Fehr, R. Vijay, et al., Dysregulated Type I Interferon and Inflammatory Monocyte-Macrophage Responses Cause Lethal Pneumonia in SARS-CoV-Infected Mice, *Cell Host Microbe* 19 (2016) 181-193. <https://doi.org/10.1016/j.chom.2016.01.007>
18. R. Channappanavar, A. R. Fehr, J. Zheng, et al., IFN-I response timing relative to virus replication determines MERS coronavirus infection outcomes, *J. Clin. Invest.* 130 (2019) 3625-3639. <https://doi.org/10.1172/JCI126363>
19. V. D. Menachery, A. Schafer, K. E. Burnum-Johnson, et al., MERS-CoV and H5N1 influenza virus antagonize antigen presentation by altering the epigenetic landscape, *Proc. Natl. Acad. Sci. U. S. A.* 115 (2018) E1012-E1021. <https://doi.org/10.1073/pnas.1706928115>
20. Tian S1, Hu W2, Niu L1, Liu H1, Xu H3, Xiao SY4. Pulmonary Pathology of Early-Phase 2019 Novel Coronavirus (COVID-19) Pneumonia in Two Patients With Lung Cancer. *J Thorac Oncol.* 2020 Feb 28. pii: S1556-0864(20)30132-5. doi: 10.1016/j.jtho.2020.02.010
21. Sharon E. Fox, Aibek Akmatbekov, Jack L. Harbert, Guang Li, J. Quincy Brown, Richard S. Vander Heide. Pulmonary and Cardiac Pathology in Covid-19: The First Autopsy Series from New Orleans. doi: <https://doi.org/10.1101/2020.04.06.20050575>
22. Franck Grillet, Julien Behr, Paul Calame, Sébastien Aubry, Eric Delabrousse. Acute Pulmonary Embolism Associated with COVID-19 Pneumonia Detected by Pulmonary CT Angiography. *Radiology.* Published Online: Apr 23 2020. <https://doi.org/10.1148/radiol.2020201544>
23. Elissa Driggin, MD, Mahesh V. Madhavan, MD, Behnood Bikdeli, MD, MS, Taylor Chuich, PharmD, Justin Laracy, MD, Giuseppe Bondi-Zoccai, MD, MStat, Tyler S. Brown, MD, Caroline Der Nigoghossian, PharmD, David A. Zidar, MD, PhD, Jennifer Haythe, MD, Daniel Brodie, MD, Joshua A. Beckman, MD, Ajay J. Kirtane, MD, SM, Gregg W. Stone, MD, Harlan M. Krumholz, MD SM, Sahil A. Parikh, MD. Cardiovascular Considerations for Patients, Health Care Workers, and Health Systems During the Coronavirus Disease 2019 (COVID-19) Pandemic. *Journal of the American College of Cardiology.* (Maret, 2020). doi:10.1016/j.jacc.2020.03.031.
24. Inciardi RM, Lupi L, Zaccone G, Italia L, Raffo M, Tomasoni D, Cani DS, Cerini M, Farina D, Gavazzi E, Maroldi R, Adamo M, Ammirati E, Sinagra G, Lombardi CM, Metra M. Cardiac Manifestations Of Coronavirus (COVID-19). *JAMA Cardiol.* 2020 Mar 27. doi: 10.1001/jamacardio.2020.1096.
25. Wang D, Hu B, Hu C, Zhu F, Liu X, Zhang J, Wang B, Xiang H, Cheng Z, Xiong Y, Zhao Y, Li Y, Wang X, Peng Z. Clinical Characteristics of 138 Hospitalized Patients With 2019 Novel Coronavirus-Infected Pneumonia in Wuhan, China. *JAMA.* 2020 Feb 07
26. Huang C, Wang Y, Li X, Ren L, Zhao J, Hu Y, Zhang L, Fan G, Xu J, Gu X, Cheng Z, Yu T, Xia J, Wei Y, Wu W, Xie X, Yin W, Li H, Liu M, Xiao Y, Gao H, Guo L, Xie J, Wang G, Jiang R, Gao Z, Jin Q, Wang J, Cao B. Clinical features of patients infected with

- 2019 novel coronavirus in Wuhan, China. *Lancet*. 2020 Feb 15;395(10223):497-506.
27. Shi S, Qin M, Shen B, Cai Y, Liu T, Yang F, Gong W, Liu X, Liang J, Zhao Q, Huang H, Yang B, Huang C. Association of Cardiac Injury With Mortality in Hospitalized Patients With COVID-19 in Wuhan, China. *JAMA Cardiol*. 2020 Mar 25.
  28. Zhou F, Yu T, Du R, Fan G, Liu Y, Liu Z, Xiang J, Wang Y, Song B, Gu X, Guan L, Wei Y, Li H, Wu X, Xu J, Tu S, Zhang Y, Chen H, Cao B. Clinical course and risk factors for mortality of adult inpatients with COVID-19 in Wuhan, China: a retrospective cohort study. *Lancet*. 2020 Mar 28;395(10229):1054-1062.
  29. Li B, Yang J, Zhao F, Zhi L, Wang X, Liu L, Bi Z, Zhao Y. Prevalence and impact of cardiovascular metabolic diseases on COVID-19 in China. *Clin Res Cardiol*. 2020 Mar 11.
  30. Guan WJ, Ni ZY, Hu Y, et al. Clinical Characteristics of Coronavirus Disease 2019 in China [e-pub ahead of print]. *N Engl J Med*. doi:10.1056/NEJMoa2002032
  31. Su, H., Yang, M., Wan, C., Yi, L.-X., Tang, F., Zhu, H.-Y., ... Zhang, C. (2020). *Renal histopathological analysis of 26 postmortem findings of patients with COVID-19 in China*. *Kidney International*. doi:10.1016/j.kint.2020.04.003
  32. Beltrán-Corbellini, Á. et al. Acute-onset smell and taste disorders in the context of Covid-19: a pilot multicenter PCR-based case-control study. *Eur J Neurol*. 2020;14273 (2020) doi:10.1111/ene.14273.
  33. Heidari, F. et al. Anosmia as a prominent symptom of COVID-19 infection. *Rhinology* (2020) doi:10.4193/Rhin20.140.
  34. Moriguchi, T. et al. A first case of meningitis/encephalitis associated with SARS-Coronavirus-2. *Int. J. Infect. Dis*. 94, 55–58 (2020).
  35. Mao, L. et al. Neurologic Manifestations of Hospitalized Patients With Coronavirus Disease 2019 in Wuhan, China. *JAMA Neurol* (2020) doi:10.1001/jamaneurol.2020.1127.
  36. Gallagher, P. E., Chappell, M. C., Ferrario, C. M. & Tallant, E. A. Distinct roles for ANG II and ANG-(1–7) in the regulation of angiotensin-converting enzyme 2 in rat astrocytes. *American Journal of Physiology-Cell Physiology* 290, C420–C426 (2006).
  37. Sellner, J., Taba, P., Öztürk, S. & Helbok, R. The need for neurologists in the care of COVID-19 patients. *Eur J Neurol*. 2020;14257 (2020) doi:10.1111/ene.14257.
  38. Doobay, M. F. et al. Differential expression of neuronal ACE2 in transgenic mice with overexpression of the brain renin-angiotensin system. *American Journal of Physiology-Regulatory, Integrative and Comparative Physiology* 292, R373–R381 (2007).
  39. Durrant, D. M., Ghosh, S. & Klein, R. S. The Olfactory Bulb: An Immunosensory Effector Organ during Neurotropic Viral Infections. *ACS Chem. Neurosci*. 7, 464–469 (2016).
  40. Bicker, J., Fortuna, A., Alves, G. & Falcão, A. Nose-to-brain Delivery of Natural Compounds for the Treatment of Central Nervous System Disorders. *Curr. Pharm. Des*. 26, 594–619 (2020).
  41. Li, Y., Bai, W. & Hashikawa, T. The neuroinvasive potential of SARS-CoV2 may play a role in the respiratory failure of COVID-19 patients. *J Med Virol* 92, 552–555 (2020).
  42. Zhang, Y. et al. Coagulopathy and Antiphospholipid Antibodies in Patients with Covid- 19. *N Engl J Med* 382, e38 (2020).
  43. Llitjos, J.-F. et al. High incidence of venous thromboembolic events in anticoagulated severe COVID-19 patients. *J. Thromb. Haemost.* (2020) doi:10.1111/jth.14869.
  44. Beun, R., Kusadasi, N., Sikma, M., Westerink, J. & Huisman, A. Thromboembolic events and apparent heparin resistance in patients infected with SARS-CoV-2. *Int J Lab Hematol* (2020) doi:10.1111/ijlh.13230.
  45. Poyiadji, N. et al. COVID-19–associated Acute Hemorrhagic Necrotizing Encephalopathy: CT and MRI Features. *Radiology* 201187 (2020) doi:10.1148/radiol.2020201187.
  46. Chen H, Guo J, Wang C, et al. Clinical characteristics and intrauterine vertical transmission potential of COVID-19 infection in nine pregnant women: a retrospective review of medical records. *Lancet* 2020 doi: [https://doi.org/10.1016/S0140-6736\(20\)30360-3](https://doi.org/10.1016/S0140-6736(20)30360-3)
  47. Chen Y, Peng H, Wang L, et al. Infants Born to Mothers With a New Coronavirus (COVID-19). *Frontiers in Pediatrics* 2020;8(104) doi: 10.3389/fped.2020.00104
  48. Li N, Han L, Peng M, et al. Maternal and neonatal outcomes of pregnant women with COVID-19 pneumonia: a case-control study. . Pre-print doi: 10.1101/2020.03.10.20033605
  49. Zhu H, Wang L, Fang C, et al. Clinical analysis of 10 neonates born to mothers with 2019-nCoV pneumonia. *TranslPediatr* 2020;9(1):51-60. doi: <http://dx.doi.org/10.21037/tp.2020.02.06>
  50. Mullins E, Evans D, Viner R, et al. Coronavirus in pregnancy and delivery: rapid review. *Ultrasound in Obstetrics and Gynaecology* (In press) doi: doi: 10.1002/uog.22014
  51. Reducing the Risk of Venous Thromboembolism during Pregnancy and the Puerperium. In: Royal College of Obstetricians & Gynaecologists, ed. *Green-top guidelines*, 2015.
  52. Practical guidance for the prevention of thrombosis and management of coagulopathy and disseminated intravascular coagulation of patients infected with COVID-19. 2020 [Available from: <https://thrombosisuk.org/covid-19-thrombosis.php>] accessed 07 April 2020.
  53. Report of the WHO-China Joint Mission on Coronavirus Disease 2019 (COVID-19)
  54. WHO Infection Prevention and Control Guidance for COVID-19 available at <https://www.who.int/emergencies/diseases/novel-coronavirus-2019/technical-guidance/infection-prevention-and-control> RCOG Coronavirus (covid-19) infection in pregnancy 17 April 2020
  55. Robinson Sabino-Silva & Ana Carolina Gomes Jardim & Walter L. Siqueira. *Clinical Oral Investigations*

- (2020) 24:1619–1621 <https://doi.org/10.1007/s00784-020-03248-x> Coronavirus COVID-19 impacts to dentistry and potential salivary diagnosis. Received: 15 February 2020 / Accepted: 17 February 2020 / Published online: 20 February 2020 # Springer-Verlag GmbH Germany, part of Springer Nature 2020
56. ECDC - European Centre for Disease Prevention and Control; European surveillance for human infection with novel coronavirus (COVID-19); 22 January, Accessed 28 Jan 2020. Available at: <https://www.ecdc.europa.eu/en/european-surveillance-human-infection-novel-coronavirus-COVID-19>
  57. World Health Organization-WHO (2020) Global surveillance for human infection with novel coronavirus (COVID-19) Interim guidance. 21 January, Accessed 28 Jan 2020. Available at: <https://www.who.int/docs/default-source/coronaviruse/20200121-global-surveillance-for-COVID-19.pdf>
  58. Wang D, Hu B, Hu C et al (2020) Clinical characteristics of 138 hospitalized patients with 2019 novel coronavirus-infected pneumonia in Wuhan, China. JAMA. <https://doi.org/10.1001/jama.2020.1585>
  59. Group of Interventional Respiratory Medicine, Chinese Thoracic Society (2020) [Expert consensus for bronchoscopy during the epidemic of 2019 Novel Coronavirus infection (Trial version)]. 43(0):E006. doi: <https://doi.org/10.3760/cma.j.issn.1001-0939.2020.0006>
  60. Zhu N, Zhang D, Wang W et al (2019) China Novel Coronavirus Investigating and Research Team. A novel coronavirus from patients with pneumonia in China. N Engl J Med.2020. <https://doi.org/10.1056/NEJMoa2001017>
  61. Chen, Lili and Zhao, Jiajia and Peng, Jinfeng and Li, Xiaoshuang and Deng, Xuliang and Geng, Zhi and Shen, Zhenyu and Guo, Fengyuan and Zhang, Qianwen and Jin, Yang and Wang, Lin and Wang, Songlin, Detection of 2019-nCoV in Saliva and Characterization of Oral Symptoms in COVID-19 Patients (March 14, 2020). Available at SSRN: <https://ssrn.com/abstract=3557140> or <http://dx.doi.org/10.2139/ssrn.3557140>
  62. Thomas Perlot, Josef M. Penninger ; ACE2 e From the renineangiotensin system to gut microbiota and malnutrition. <http://dx.doi.org/10.1016/j.micinf.2013.08.003>
  63. Yuan Tian, Long Rong ; Review article: gastrointestinal features in COVID-19 and the possibility of faecal transmission. Aliment Pharmacol Ther. 2020;51:843–851.
  64. Ferdinando D’Amico, Daniel C. Baumgart, Silvio Danese, Laurent Peyrin-Biroulet ; Diarrhea during COVID-19 infection: pathogenesis, epidemiology, prevention and management. Clinical Gastroenterology and Hepatology Accepted Date: 2 April 2020.
  65. Sabela Lens, Jeffrey V Lazarus ; Enteric involvement of coronaviruses: is faecal–oral transmission of SARS-CoV-2 possible? [www.thelancet.com/gastrohep](http://www.thelancet.com/gastrohep) Vol 5 335, April 2020
  66. Darlenski, R., & Tsankov, N. Covid-19 pandemic and the skin - What should dermatologists know? Clinics in Dermatology. 2020. doi:10.1016/j.clindermatol.2020.03.012
  67. Estébanez, A., Pérez-Santiago, L., Silva, E., Guillen-Climent, S., García-Vázquez, A., & Ramón, M. D. Cutaneous manifestations in COVID-19: a new contribution. Journal of the European Academy of Dermatology and Venereology. 2020. doi:10.1111/jdv.16474
  68. V. M. Corman, O. Landt, M. Kaiser, et al., Detection of 2019 novel coronavirus (2019-nCoV) by real-time RT-PCR, Euro. Surveill. 25 (2020). <https://doi.org/10.2807/1560-7917.ES.2020.25.3.2000045>
  69. Y. Pan, H. Guan, S. Zhou, et al., Initial CT findings and temporal changes in patients with the novel coronavirus pneumonia (2019-nCoV): a study of 63 patients in Wuhan, China, Eur. Radiol. (2020). <https://doi.org/10.1007/s00330-020-06731-x>
  70. H. Shi, X. Han, C. Zheng, Evolution of CT Manifestations in a Patient Recovered from 2019 Novel Coronavirus (2019-nCoV) Pneumonia in Wuhan, China, Radiology (2020) 200269. <https://doi.org/10.1148/radiol.2020200269>
  71. M. Chung, A. Bernheim, X. Mei, et al., CT Imaging Features of 2019 Novel Coronavirus (2019-nCoV), Radiology (2020) 200230. <https://doi.org/10.1148/radiol.2020200230>
  72. Scollo, S., La Camera, G., Neri, S., Grasso, C., Cubisino, R., Bonsignore, C., La Rosa, V., Astuto, M. Acquired angioedema of the glottis, larynx and neck in a patient affected by SLE: Case report(2018) European Journal of Molecular and Clinical Medicine, 5, pp. 16-19. DOI: 10.5334/ejmcm.247
  73. P. C. Woo, S. K. Lau, B. H. Wong, et al., Differential sensitivities of severe acute respiratory syndrome (SARS) coronavirus spike polypeptide enzyme-linked immunosorbent assay (ELISA) and SARS coronavirus nucleocapsid protein ELISA for serodiagnosis of SARS coronavirus pneumonia, J. Clin. Microbiol. 43 (2005) 3054-3058. <https://doi.org/10.1128/JCM.43.7.3054-3058.2005>
  74. Mossa-Basha, M., Meltzer, C.C., Kim, D.C., Tuite, M.J., Kolli, K.P., Tan, B.S., 2020. Radiology Department Preparedness for COVID-19: Radiology Scientific Expert Panel. Radiology 200988. <https://doi.org/10.1148/radiol.2020200988>
  75. Raptis, C.A., Hammer, M.M., Short, R.G., Shah, A., Bhalla, S., Bierhals, A.J., Filev, P.D., Hope, M.D., Jeudy, J., Kliggerman, S.J., Henry, T.S., 2020. Chest CT and Coronavirus Disease (COVID-19): A Critical Review of the Literature to Date 4.
  76. Gietema, H.A., Zelis, N., Nobel, J.M., Lambriks, L.J., van Alphen, L.B., Lashof, A.M.O., Wildberger, J.E., Nelissen, I.C., Stassen, P.M., n.d. CT in relation to RT-PCR in diagnosing COVID-19 in the Netherlands: a prospective study 16

77. CT Provides Best Diagnosis for Novel Coronavirus (COVID-19) [WWW Document], 2020. . Imaging Technology News. URL <https://www.itnonline.com/content/ct-provides-best-diagnosis-novel-coronavirus-covid-19> (accessed 4.6.20).
78. Bernheim, A., Mei, X., Huang, M., Yang, Y., Fayad, Z.A., Zhang, N., Diao, K., Lin, B., Zhu, X., Li, K., Li, S., Shan, H., Jacobi, A., Chung, M., 2020. Chest CT Findings in Coronavirus Disease-19 (COVID-19): Relationship to Duration of Infection. *Radiology* 200463. <https://doi.org/10.1148/radiol.2020200463>
79. Pan, F., Ye, T., Sun, P., Gui, S., Liang, B., Li, L., Zheng, D., Wang, J., Hesketh, R.L., Yang, L., Zheng, C., 2020. Time Course of Lung Changes On Chest CT During Recovery From 2019 Novel Coronavirus (COVID-19) Pneumonia. *Radiology* 200370. <https://doi.org/10.1148/radiol.2020200370>