

Effect of the Combination of Demineralization Freeze Dried Dentin Matrix (DFDDM) and *Moringa oleifera* Lam on Osteoprotegerin (OPG) and Receptor Activator of Nuclear Factor Kappa B Ligand (RANKL) as a Marker of Bone Remodeling

Arni Irawaty Djais¹, Harun Achmad², Dewang Dewiayu³, Austin Bertilova Carmelita⁴, Iwan Aflanie⁵, Bayu Indra Sukmana⁶, Huldani⁷

¹Department of Periodontology, Faculty of Dentistry, Hasanuddin University, Makassar, Indonesia

²Department of Pediatric Dentistry, Faculty of Dentistry Hasanuddin University, Makassar, Indonesia

³Professional Program Student, Faculty of Dentistry, Hasanuddin University Makassar Indonesia

⁴Department of Physiology, Faculty of Medicine, Palangkaraya University, Palangkaraya, Central Kalimantan, Indonesia

⁵Department of Forensic, Faculty of Medicine, Lambung Mangkurat University, Banjarmasin, South Kalimantan, Indonesia

⁶Department of Oral Radiology, Dentistry Medical Faculty, Lambung Mangkurat University, Banjarmasin, South Kalimantan, Indonesia

⁷Department of Physiology and Immunology, Faculty of Medicine, Lambung Mangkurat University, Banjarmasin, South Kalimantan, Indonesia

Corresponding E-mail: harunachmader@gmail.com

Article History:

Submitted: 16.04.2020

Revised: 10.05.2020

Accepted: 28.06.2020

ABSTRACT

Background: The socket preservation has important role in alveolar bone resorption after tooth extraction. Various graft materials can be used in socket preservation must have osteoconductive, osteoinductive and osteoproliferation properties. Autogenous bone graft from dentin can be used because it has good osteoinductive and osteoconductive properties. One of the active substances of *Moringa oleifera* (MO) is flavonoids that have several beneficial characteristics as an anti-inflammatory. The combination of anti-inflammatory with MO extract and Demineralization Freeze Dried Dentin Matrix (DFDDM) is expected to provide a good response to bone formation.

Aim: To determine the potential of combination *Moringa oleifera* and DFDDM in formation of OPG and RANKL expression post extraction cavia cobaya's tooth.

Method: The mandibular incisors of 45 *Cavia cobaya* were extracted and divided into five groups subjected to different socket preservation treatments sequentially with MO, DFDDM, combination of MO and DFDDM, Gamacha® and polyethylene glycol (PEG). The *cavia cobaya* were examined on days 7, 14 and 21 after which the specimens were sacrificed and examined using an immunohistochemical technique.

The resulting data were then analyzed using one-way ANOVA and Tukey's honestly significant difference tests.

Result: The One Way Anova test results showed a significant difference in OPG and RANKL between the groups ($p < 0.05$) on day 7, 14 and 21 observation. The highest mean amount of OPG and lowest mean amount of RANKL were found in the third group.

Conclusion: Combination of MO and DFDDM can effectively generate OPG and RANKL expressions during the preservation of tooth extraction sockets.

Keywords: Demineralization Freeze Dried Dentin Matrix (DFDDM), *Moringa oleifera*, Osteoprotegerin (OPG), Receptor Activator of Nuclear Factor Kappa B Ligand (RANKL)

Correspondence:

Harun Achmad

Department of Pediatric Dentistry, Hasanuddin University, Makassar, South Sulawesi, Indonesia

E-mail: harunachmader@gmail.com

DOI: [10.31838/srp.2020.6.113](https://doi.org/10.31838/srp.2020.6.113)

©Advanced Scientific Research. All rights reserved

INTRODUCTION

The alveolar bone is a bone structure that supports the teeth. When the bone lost its structures and volume due to the extraction of teeth or periodontal disease, it will affect the stability, retention, and support for a denture, fixed denture, and dental implant placement and it makes the patient uncomfortable. (1)

Basically, wound healing in a socket has a similarity with the soft tissue healing in a socket, except it involves the healing of bone consists of (1) clotting, (2) re-epithelialization, (3) the formation of granulation tissue (4) bone formation. (2) In the remodeling process of bone formation, the dimensions of the socket wall changed. A large number of the heights and width of the bone will be lost due to resorption of the wall socket, above 25% in the 1st year and will increase over 40-60% over 3 years later. In the posterior area, average bone loss exceeds up to 50% over the first year after the extraction procedure. Especially if the buccal plate lost during extractions, it could result in limitations of the buccal-lingual dimension, which cause reduced sufficient space for implant placement. (3) Socket grafting with bone

substitutes is a promising act to prevent bone loss after an extraction. (2)

The balance of bone resorption and bone deposition is determined by the activity of two types of main cells, osteoclasts, and osteoblasts. (4) Alveolar bone resorption process begins with the bond between Receptor Activator of Nuclear Factor Kappa B Ligand (RANKL) and the RANK receptor on preosteoclasts. RANKL /RANK are the key in the regulation of the osteoclastogenesis process. Osteoclast formation also influenced by proinflammatory cytokines, such as Tumor necrosis Factor- α (TNF- α), interleukin-1 (IL-1) and interleukin-6 (IL-6). The osteoclast resorption mediation process usually takes about 1-4 weeks (4),(5). The role of osteoprotegerin (OPG) is to protect the bone from excessive resorption by binding to RANKL; therefore RANKL doesn't bind to RANK. RANKL and OPG bonds are the main determinant of bone mass and bone strength. (6) Ridge preservation is a procedure in the tooth socket by using graft material that can reduce the bone and soft tissue loss after tooth extraction which aims to compensate for the buccal bone wall biological resorption and maintain bone

volume and bone structure, therefore it can function optimally and has a good aesthetic. (7), (5), (8)

The ideal bone graft should have osteoconduction, osteoinduction, and osteogenesis characteristics. Autogenous bone has these three characteristics; therefore it becomes the gold standard in alveolar bone regenerative procedures. (1) Autogenous bone weakness is an infection risk from the donor area, the second surgery, the possibility of donor area death, and lack of resources for autograft led to the development of bone substitute as an alternative to autogenous bone. (9) Dentin and bone were biochemically similar, so it can be considered as bone regenerative material. Demineralized Dentin Matrix (DDM) is an organic material derived from dentin that has an osteogenic capability. (10) Demineralized Freeze-Dried Dentin Matrix is the formation of DDM that has been through the process of freeze-dried. (9)

Moringa plant known with the Latin name *Moringa oleifera* Lam is a plant contains active substance carotenoids, polyphenols, phenolic acids, flavonoids, alkaloids, glucosinolates, isothiocyanates, tannins, and saponins. (11) Moringa leaves can inhibit cytokine production by macrophages (Tumor Necrosis Factor-alpha (TNF- α), interleukin-6 (IL-6) and IL-8)), which caused by Lipopolysaccharide (LPS). Other studies have reported that the concentration of Moringa leaves can reduce gene expression and production of inflammatory markers in macrophages. Moringa leaf extract can stimulate cellular and humoral immune response through an increase in white blood cells, neutrophils, and immunoglobulins serum. The quercetin, which is a part of Moringa leaves flavonoid, can be involved in a decrease in the inflammatory process by blocking the action of a neutral factor-kappa Beta (NF-kB). Quercetin can stimulate osteoblasts and increase bone formation. (11)

Anti-inflammatory combination of Moringa leaf extract and osteoconductive and osteoinductive characteristics of the demineralization Freeze-Dried Dentin Matrix (DFDDM) is expected to give a good response to the bone formation. Based on the explanation above, this study aims to determine the formation of OPG and RANKL immune responses in alveolar bones after extraction of *Cavia cobaya* teeth by administering a combination of *Moringa oleifera* leaf extract and Demineralized Freeze-Dried Dentin Matrix (DFDDM).

MATERIALS AND METHODS

Type and design of the study

This research is an experimental research laboratory with a research design using a post-test only control group design.

Location and time of the study

This research was conducted in June to October in the Chemistry Laboratory and Biopharmaca Laboratory of Pharmacy Faculty of Hasanuddin University,

Pharmaceutical Laboratories of State Islamic University of Makassar, College of Pharmacy Research Laboratory of Makassar, Integrated Biotechnology Laboratory, Faculty of Animal Husbandry of Hasanuddin University, and Installation Laboratory Center for Biomaterials and Anatomy Pathology Laboratory of Hasanuddin University Teaching Hospital.

Research procedure

This study uses instruments and materials for Moringa leaf extract 2% manufacture, DFDDM manufacture; Instruments and materials for dental extractions; instruments for DFDDM applications; instruments for Moringa leaf extract and DFDDM application at the former revocation sockets, and tools for the immunohistology examinations, polyclonal anti-OPG, and anti-RANKL materials.

The subjects of this study were 45 *Cavia cobaya*, 300-350 grams, 90-120 days old, male, and healthy (non-dull hair, no hair loss, physically active, and have a good feed intake). This study was received by the Ethics Commission of the Faculty of Dentistry of Hasanuddin University in number

This study began with the extraction of *Moringa oleifera* leaves by maceration method using 70% ethanol was done in the Pharmaceutical Laboratories State Islamic University of Makassar, then the making process of Demineralized Freeze-Dried Dentin Matrix (DFDDM) was done in Integrated Biotechnology Laboratory Animal Husbandry Faculty of Hasanuddin University, College of Pharmacy Research Laboratory of Makassar, after that the guinea pig tooth was extracted and application of materials at the socket is divided into 5 treatment groups based on days of observation, 7, 14, and 21 days. The first group was given dried Moringa leaf extract (MO) 2% (0,5-gram MO in 24-gram PEG). The second group was given 0,5-gram DFDDM. The third group was given a combination (0,5-gram MO, 0,5-gram DFDDM, and 24-gram PEG). Group IV was given 0,5-gram Gamacha® bone graft as a positive control and Group V was given polyglikol (PEG) as a negative control of mandibular incisor retraction socket.

On the 7th, 14th and 21st days of observation, the guinea pig was sacrificed and *Cavia cobaya*'s mandible was taken and stored in a 70% formalin solution. OPG and RANKL expression was observed by immunohistochemical polyclonal anti- OPG and anti-RANKL. Observation of the preparation and measurement of OPG RANKL expression was done by using a light microscope, 1000x magnification. The Shapirowalik sample test was performed at the observation result to determine the normality of the distribution of the samples, after that the Levene test was performed to determine the homogeneity of the data, afterward, One-way ANOVA and Tukey HSD post hoc test was done to determine the differences between the study groups.

RESEARCH RESULT

Table.1 Immunohistochemistry observation on the mandibular incisor extraction socket

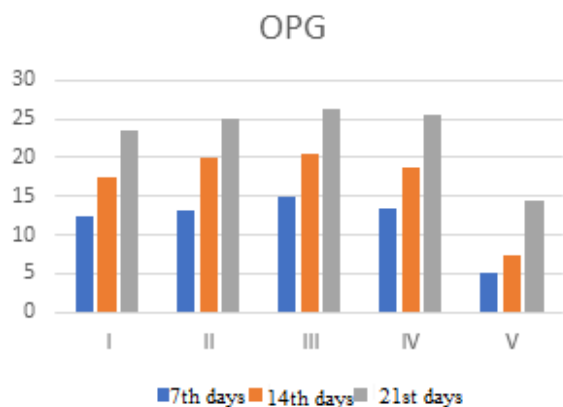


Figure 1: Graph of the average OPG expression on immunohistochemical observation on the 7th, 14th, and 21st days

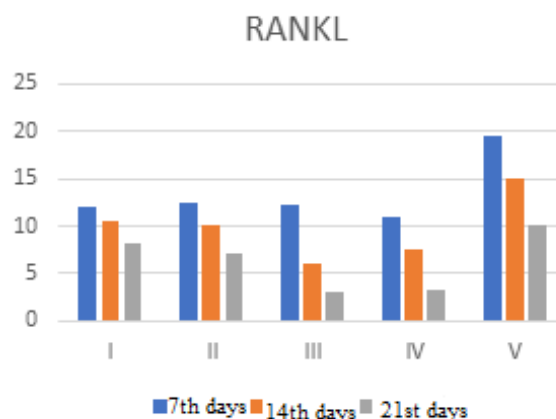


Figure 2: Graph of the average of RANKL expression on immunohistochemical observation on the 7th, 14th, and 21st days

Based on the graphic images above the average OPG expression on immunohistochemical observations on days 7, 14, and 21, all groups descriptively experienced an

increase in OPG expression. In contrast to the expression of RANKL immunohistochemical observations days 7, 14, and 21, all groups descriptively decreased.



Figure 3: The arrows showed the RANKL expression on immunohistochemical observation on the 7th day at the group I, II, III, IV, and V.



Figure 4: The arrows showed the RANKL expression on immunohistochemical observation on the 14th day at the group I, II, III, IV, and V



Figure 5: The arrows showed the RANKL expression on immunohistochemical observation on the 21st day at the group I, II, III, IV, and V



Figure 6: The arrows showed the OPG expression on immunohistochemical observation on the 7th day at the group I, II, III, IV, and V



Figure 7: The arrows showed the OPG expression on immunohistochemical observation on the 14th day at the group I, II, III, IV, and V



Figure 8: The arrows showed the OPG expression on immunohistochemical observation on the 21st day at the group I, II, III, IV, and V

Table 1: The average of OPG and RANKL expressions amount on the immunohistochemical observation at the mandibular incisor extraction socket

Group	N	Observation	OPG ($\bar{x} \pm SD$)	p* Value	RANKL ($\bar{x} \pm SD$)	p* Value
I	3	Day 7	12.50 ± 0.50	0.000*	12.00 ± 2.00	0.034*
	3	Day 14	17.50 ± 1.50		10.50 ± 0.50	
	3	Day 21	23.50 ± 3.50		8.17 ± 1.04	
II	3	Day 7	13.16 ± 0.50	0.000*	12.50 ± 0.50	0.000*
	3	Day 14	20.00 ± 2.00		10.0 ± 1.00	
	3	Day 21	25.00 ± 1.00		7.17 ± 0.76	
III	3	Day 7	15.00 ± 1.00	0.000*	12.17 ± 1.25	0.000*
	3	Day 14	20.50 ± 1.50		6.00 ± 1.00	
	3	Day 21	26.33 ± 0.52		3.00 ± 1.00	
IV	3	Day 7	13.33 ± 2.08	0.000*	11.00 ± 1.00	0.001*
	3	Day 14	18.67 ± 1.52		7.50 ± 1.32	
	3	Day 21	25.67 ± 1.52		3.33 ± 1.52	
V	3	Day 7	5.00 ± 1.04	0.019*	19.50 ± 1.50	0.004*
	3	Day 14	7.33 ± 1.52		15.00 ± 3.00	
	3	Day 21	7.16 ± 2.00		10.00 ± 1.00	

*Oneway Anova; p<0.05; significant

Based on Table 1, Immunohistochemical observation at the mean of OPG and RANKL expression at the guinea pigs mandibular incisor extraction socket, the Oneway Anova

test showed the entire treatment groups had a significant value of p <0.05, which means there is a significant difference in each treatment group.

Table 2: Tukey's Honest Significant Difference (HSD) test at the averages expression of immunohistochemical observations on the mandibular incisor extraction socket

Group	Observation	Comparison	p* OPG Value	p* RANKL Value
I	Day 7	Day 14	0.073	0.409
		Day 21	0.002*	0.029*
	Day 14	Day 21	0.037	0.161
II	Day 7	Day 14	0.005*	0.018*
		Day 21	0.000*	0.000*
	Day 14	Day 21	0.020*	0.010*
III	Day 7	Day 14	0.006*	0.001*
		Day 21	0.000*	0.000*
	Day 14	Day 21	0.005*	0.035*
IV	Day 7	Day 14	0.022*	0.038*
		Day 21	0.000*	0.001*
	Day 14	Day 21	0.006*	0.018*
V	Day 7	Day 14	0.616	0.076
		Day 21	0.050*	0.003*
	Day 14	Day 21	0.059	0.052

*Post Hoc Tukey HSD; p<0.05; significant

Immunohistochemical observations for OPG at the mandibular incisor extraction socket, group I showed a significance value of p <0.05, which means there is a significant difference between the decreased expression of

NFkB on the 7th and 14th days but showed a significant value of p > 0.05 on the 14th and 21st days, which means there is no significant difference. Group I and V, showed a significance value p > 0.05, which means there is no

significant difference between the increase of the NFkB expression on the 7th days and 14th and on the 14th and 21st days. In the third group that use the combination (0,5-gram MO, 0,5-gram DFDDM, and 24-gram PEG) and group IV that was given 0.5 grams Gamacca® bone graft, showed a significant value of $p < 0.05$, which means there is a significant difference between the increase of NFkB expression on the 7th and 14th days and the 14th to 21st days. Immunohistochemistry observation of RANKL in the mandibular incisor extraction socket, almost all groups of

observation days showed a significance value of $p < 0.05$ which means that there was a significant difference between decreased RANKL expression on the 7th and 14th days, and on the 14th and 21st days. However, it was different from the groups I which used *Moringa oleifera* and group V which used PEG, on the 7th to 14th days and the 14th to 21st days of observation showed a significance value of $p > 0.05$ which means there is no significant difference between decreased RANKL expression on the 7th and 14th days, and 14th and 21th days.

Table 3: Tukey's Honest Significant Difference (HSD) test of averages expression on OPG immunohistochemical observation on the 7th day on the mandibular incisor extraction socket

Group	I	II	III	IV	V
I		0.971	0.234	0.938	0.000*
II			0.497	1.000	0.000*
III				0.580	0.000*
IV					0.000*
V					

*Post Hoc Tukey HSD; $p < 0.05$; significant

Based on table 3, further different test of OPG immunohistochemical observations on 7th days socket extraction at the mandibular incisors, group V to groups I, II, III, and IV showed a significance value of $p < 0.05$ which means there is a significant difference between differences

mean number of OPG expressions or have a different effect. The other group showed a significance value of $p > 0.05$ which means there was no significant difference between the differences mean expression of OPG or had the same effect between one treatment group and the other.

Table 4: Tukey's Honest Significant Difference (HSD) test of average expression on OPG immunohistochemical observation on the 14th day on the mandibular incisor extraction socket

Group	I	II	III	IV	V
I		0.382	0.233	0.898	0.000*
II			0.995	0.847	0.000*
III				0.650	0.000*
IV					0.000*
V					

*Post Hoc Tukey HSD; $p < 0.05$; significant

Based on table 4, further different test of OPG immunohistochemical observations on 14th days socket extraction at the mandibular incisors, group V to groups I, II, III, and IV showed a significance value of $p < 0.05$ which means there is a significant difference between the mean

difference number of OPG expression or have a different effect. The other group showed a significance value of $p > 0.05$ which means there was no significant difference between the differences of OPG expression mean or had the same effect between one treatment group and the other.

Table 5: Tukey's Honest Significant Difference (HSD) test of average expression on OPG immunohistochemical observation on the 21st day on the mandibular incisor extraction socket

Group	I	II	III	IV	V
I		0.963	0.739	0.877	0.018*
II			0.976	0.998	0.007*
III				0.998	0.003*
IV					0.004*
V					

*Post Hoc Tukey HSD; $p < 0.05$; significant

Based on table 5, further different test of OPG immunohistochemical observations on the 21st days at the mandibular incisors extraction socket, group V to groups I, II, III, and IV showed a significance value of $p < 0.05$ which means there is a significant difference between the mean

difference number of OPG expression or have a different effect. The other group showed a significance value of $p > 0.05$ which means there was no significant difference between the differences of OPG expression mean or had the same effect between one treatment group and the other.

Table 6: Tukey's Honest Significant Difference (HSD) test of average expression on RANKL immunohistochemical observation on the 7th day on the mandibular incisor extraction socket

Group	I	II	III	IV	V
I		0.990	1.000	0.887	0.000*
II			0.998	0.662	0.001*
III				0.882	0.000*
IV					0.000*
V					

*Post Hoc Tukey HSD; $p < 0.05$; significant

Based on table 6, further different test of RANKL immunohistochemical observations on the 7th days at the mandibular incisors extraction socket, group V to groups I, II, III, and IV showed a significance value of $p < 0.05$ which means there is a significant difference between the mean

difference number of RANKL expression or have a different effect. The other group showed a significance value of $p > 0.05$ which means there was no significant difference between the differences of RANKL expression mean or had the same effect between one treatment group and the other.

Table 7: Tukey's Honest Significant Difference (HSD) test of average expression on RANKL immunohistochemical observation on the 14th day on the mandibular incisor extraction socket

Group	I	II	III	IV	V
I		0.995	0.041*	0.228	0.041*
II			0.074	0.376	0.023*
III				0.783	0.000*
IV					0.001*
V					

*Post Hoc Tukey HSD; $p < 0.05$; significant

Based on table 7, further different test of RANKL immunohistochemical observations on the 14th days at the mandibular incisors extraction socket, group V to groups I, II, III, and IV showed a significance value of $p < 0.05$ which means there is a significant difference between the mean

difference number of RANKL expression or have a different effect. The other group showed a significance value of $p > 0.05$ which means there was no significant difference between the differences of RANKL expression mean or had the same effect between one treatment group and the other.

Table 8: Tukey's Honest Significant Difference (HSD) test of average expression on RANKL immunohistochemical observation on the 21st day on the mandibular incisor extraction socket

Group	I	II	III	IV	V
I		0.794	0.001*	0.002*	0.311
II			0.006*	0.011*	0.061*
III				0.995	0.000*
IV					0.000*
V					

*Post Hoc Tukey HSD; $p < 0.05$; significant

Based on table 8, further different test of RANKL immunohistochemical observations on the 21st days at the mandibular incisors extraction socket, group V to groups I, II, III, and IV showed a significance value of $p < 0.05$ which means there is a significant difference between the mean difference number of RANKL expression or have a different effect. The other group showed a significance value of $p > 0.05$ which means there was no significant difference between the differences of RANKL expression mean or had the same effect between one treatment group and the other.

tooth extraction by placing various graft materials in the newly extracted socket. Various materials that can be used are autogenous, allogeneic, xenograft, and alloplast material, but to get satisfactory results, graft material must have osteoconduction, osteoinduction, and osteoproliferation characteristic. (1)

The process of bone remodeling requires a balance of osteoblast and osteoclast activity, osteoprotegerin (OPG) expression studies or commonly known as osteoclast inhibitory factors, as well as RANKL expression studies or Receptor Activator of Nuclear Factor Kappa B Ligand is conducted to examine the potential mechanisms involved in osteocurrative effects. In this study, bone formation using hydroxyapatite autogenous bone graft can provide good results which increased OPG expression and decreased RANKL expression as indicators of bone formation. (13)

DISCUSSION

In this study, the extraction of lower incisors was performed on *Cavia cobaya*. *Cavia cobaya* is the most suitable experimental animal in this study because its immune response was similar to humans. (12) Socket preservation in the alveolar bone has an important role, especially after

Bone remodeling is affected by the balance between RANKL-RANK bonds and OPG production. Numerous studies show that bone remodeling depends on the ratio of RANKL to OPG. If RANKL expression is higher, then the bone resorption occurs, conversely, if OPG expression is higher, then bone formation occurs. Therefore, OPG is required to maintain the balance of bone metabolism by preventing bone resorption and increasing bone density and strength. Some studies also show that when RANKL expression increases, OPG expression decreases or it is not at the same level as RANKL and vice versa. (14)

Autogenous bone graft has been used to repair bone defects because dentin and bone have a main characteristic, osteoinductive. (15) Demineralized dentin matrix (DDM) contains type-I collagen along with growth factors such as BMP-2 and fibroblast growth factors. This bioactive molecule contributes to osteoinduction and osteoconduction of human teeth as graft material. (1) In table 1, the application of autograft material using the Demineralized Freeze-Dried Dentin Matrix (DFDDM) autograft material on the 7th, 14th and 21st days observation showed an increase in the number of OPG expression significant as well as a significant decrease in the number of RANKL expressions using the Oneway Anova test in the DFDDM group. The dentin matrix can improve the repair of mineral dentin tissue in the tooth and also bone repair so that DDM can be represented as representing a physiologically optimized matrix model to promote osteogenic signaling. (16) Autograft material that is inserted into the post-extraction socket, the result can be used as a framework for the new bone growth which derived from osteoblasts at the bottom of the socket. (17)

The results of this study also showed an increase in OPG expression and a decrease in RANKL on the 7th, 14th, and 21st days of observation using the Oneway Anova test in the group of *Moringa oleifera* leaf extraction as shown in Table 1. This study is in line with Soekobagiono et al's study which showed a decrease in RANKL on the 7th to the 30th days by adding *Moringa oleifera* to the socket preservation. (17) *Moringa oleifera* is a plant that is rich in protein, flavonoids, saponins, alkaloids, tannins, essential amino acids, as well as being antioxidants. (18) Through the antioxidant mechanisms, polyphenols have been shown to reduce the detrimental effects of oxidative stress on osteoblasts, through inhibition TNF- α which induces apoptosis. (19) This is in line with research conducted by Li et al (2005) which proves that phytoestrogens increase the differentiation of MSCs and inhibit adipogenic differentiation through non-genomic ER-mediated mechanisms. (20) Additionally, the compound content of flavonoids in *Moringa oleifera* especially kaempferol and quercetin can inhibit prostaglandin synthesis, PGE-2 which decreases macrophage infiltration. The decrease in macrophage cells will be followed by a decrease in inflammatory mediators, such as histamine, serotonin, and the three pro-inflammatory cytokines (TNF α , IL-1, IL-6). (21) Decreasing pro-inflammatory mediators can reduce RANKL production in wound healing after extraction. (17) And also induces a decrease in bone resorption. (22) Prostaglandins (PGE-2) are known to play a

role in stimulating osteoclast formation directly or indirectly through RANKL, resulting in differentiation and fusion of osteoclast precursors into osteoclasts. Therefore, the presence of barriers to PGE-2 and cytokine synthesis can function as inhibitors of osteoclast formation so that the number of osteoclast cells and proinflammatory cytokines can also inhibit osteoprotegerin (OPG). In other words, decreased PGE-2 synthesis indirectly induces bone formation only by activating the biological cascade of osteoblastogenesis by deactivating RANKL in wound healing after extraction. (22)

Based on table 1, the osteoconductive and osteoinductive characteristic of the two ingredients above (a combination of *Moringa oleifera* and DFDDM) can significantly increase the number of OPG expressions and reduce the number of RANKL expressions observed at the 7th, 14th and 21st days using the One-way Anova test and give the best effect of other groups (table 3-9). This study shows that the combination of DFDDM and *Moringa oleifera* can increase the amount of OPG expression in the post-extraction healing process. This is due to the presence of a combination of DFDDM and *Moringa oleifera* in socket preservation, DFDDM autograft has osteoinduction and osteoconductive characteristic of DDM (demineralized dentin matrix), according to Murata et al's research which confirms that DDM granules derived from M3 teeth induce bone formation and cartilage bone in rat subcutaneous tissue, the sequence for bone induction is similar to demineralized bone matrix (15).

Table 2 Tukey's Honest Significant Difference (HSD) test, a combination of DFDDM and *Moringa oleifera* that was given at the Group III showed a significant increase in OPG observations and a decrease in RANKL on the 7th to 14th days of observation, as well as day 14 to day 21. Unlike the other groups, group I which is given *Moringa oleifera* and PEGs did not show a significant increase on 14th to 21st days of observation. The combination of this material supports the formation of new bone facilitated by DFDDM as a scaffold. The osteoconductive nature of DDM is in line with the research conducted by de Oliveira et al, who performed BMP-2 and BMP-4 immunostaining on osteoblasts during the healing process of the second molar socket of mice applied with human DDM. (Jain et al., 2019) Moreover, the presence of *Moringa oleifera* helps to increase OPG expression because it has an indirect osteoinductive characteristic derived from the flavonoid content in it (quercetin) which is proven to have an antioxidant characteristic that can stimulate osteoblast proliferation and differentiation. Therefore, the expression of OPG will increase. Increased OPG is very influential on osteoclast activation because OPG acts as a "decoy receptor" for RANKL by inhibiting the interaction of RANKL and RANK on osteoclast precursor cell membranes, thereby preventing osteoclastogenesis. Inhibition of osteoclastogenesis will reduce the speed and intensity of osteoclastogenesis and cause apoptosis in osteoclasts so that it can reduce bone resorption and increase bone formation. (23) (24) (25) (26) Likewise, the tannins contained in *Moringa* leaf extract can inhibit osteoclast differentiation. (27) (28) (29)

Group IV positive control of Gamacha® bone graft material had more or less same effect as group II with DFDDM administration, with an increase in OPG at the 7th, 14th and 21st days, and also an increase in the further test at the 7th days until 14th days and on the 14th days to 21st days (table 3-9). Gamacha® bone graft material has been used today. Unlike DFDDM, Gamacha® only has good osteoconductive power, does not have osteoinductive or osteoproliferative characteristics. (Gamacha, 2019) Group V that was given PEG is a negative group and does not show a significant increase in OPG and a decrease in RANKL.

Giving a combination of DFDDM graph material and *Moringa oleifera* can increase the amount of OPG expression and reduce the amount of RANKL expression in socket preservation after Cavia cobaya tooth extraction.

REFERENCES

1. Joshi C, Dani N, Khedkar S. Alveolar ridge preservation using autogenous tooth graft versus beta-tricalcium phosphate alloplast: A randomized, controlled, prospective, clinical pilot study. *J Indian Soc Periodontol*. 2016;20(4):429.
2. Xiao W, Wang Y, Pacios S, Li S, Graves DT. Cellular and Molecular Aspects of Bone Remodeling. *Front Oral Biol*. 2015;18(33):9–16.
3. Hassan K, Alagl A. Immediate Dental Implants and Bone Graft. *Implant Dent*. 2011;(September).
4. Kini U, Nandeesh BN. Physiology of Bone Formation, Remodeling, and Metabolism. 2012;
5. Rostiny, Djulaeha E, Hendrijantini N, Pudijanto A. The effect of combined *Moringa oleifera* and demineralized freeze-dried bovine bone xenograft on the amount of osteoblast and osteoclast in the healing of tooth extraction socket of Cavia cobaya. *Dent J (Majalah Kedokt Gigi)*. 2016;37(56):38–43.
6. Boyce BF, Xing L. Functions of RANKL / RANK / OPG in bone modeling and remodeling. 2008;473:139–46.
7. Fee L. Socket preservation. *Br Dent J*. 2017;222(8):579–82.
8. Jmag H, De S, Ga VDW, Byrne G. Socket preservation of implant sites. *J Am Dent Assoc*. 2012;143(10):1139–40.
9. Kabir MA, Murata M, Kusano K, Akazawa T, Shibata T. Autogenous Demineralized Dentin Graft for Third Molar Socket Regeneration - A Case Report. *Dentistry*. 2015;5(11):11–4.
10. Bhattacharjya C, Gadicherla S, Kamath AT, Smriti K, Pentapati KC. Tooth derived bone graft material. *J Korean Assoc Oral Maxillofac Surg*. 2016;7(1):32–5.
11. Vergara-Jimenez M, Almatrafi M, Fernandez M. Bioactive Components in *Moringa oleifera* Leaves Protect against Chronic Disease. Vol. 6, *Antioxidants*. 2017. hal. 91.
12. Kristiawati D. I. INTRODUCTION A. Guinea Pig's Background [. 2017;1–3.
13. Patel C, Rangrez A, Parikh P. The anti-osteoporotic effect of *Moringa oleifera* on osteoblastic cells : SaOS 2. *IOSR J Pharm Biol Sci*. 2013;5(2):10–7.
14. Kapasa E, Giannoudis P, Jia X, Hatton P, Yang X. The Effect of RANKL/OPG Balance on Reducing Implant Complications. *J Funct Biomater*. 2017;8(4):42.
15. Jain S, Agrawal N, Dwivedi A, Bajaj S. A modified technique for fabrication of custom-made afterload brachytherapy appliance. *J Indian Prosthodont Soc*. 2019;19(1):79–82.
16. Avery S, Avery S, Sadaghiani L, Sloan A, Waddington R. Analysing The Bioactive Makeup Of Demineralised Dentine Matrix On Bone Marrow Mesenchymal Stem Cells For Enhanced Bone Repair. *Eur Cells Mater*. 2017;34:1–14.
17. Soekobagiono S, Alfiandy A, Dahlan A. RANKL expressions in preservation of surgical tooth extraction treated with *Moringa oleifera* leaf extract and demineralized freeze-dried bovine bone xenograft. *Dent J (Dentistry Magazine)*. 2018;50(3):149.
18. Kou X, Li B, Olayanju JB, Drake JM, Chen N. Nutraceutical or Pharmacological Potential of *Moringa oleifera* Lam. 2018;10(3):343.
19. Choi J. Oxidative stress, endogenous antioxidants, alcohol, and hepatitis C: Pathogenic interactions and therapeutic considerations. *Free Radic Biol Med [Internet]*. 2012;52(7):1135–50. Tersedia pada: <http://dx.doi.org/10.1016/j.freeradbiomed.2012.01.008>
20. Horcajada M-N, Offord E. Naturally Plant-Derived Compounds: Role in Bone Anabolism. *Curr Mol Pharmacol*. 2012;5(2):205–18.
21. Tan WS, Arulselvan P, Karthivashan G, Fakurazi S. *Moringa oleifera* Flower Extract Suppresses the Activation of Inflammatory Mediators in Lipopolysaccharide-Stimulated RAW 264 . 7 Macrophages via NFK B Pathway. *Hindawi Publ Corp Mediat*. 2015;2015:1–11.
22. Schett G. Effects of inflammatory and anti-inflammatory cytokines on the bone. *Eur J Clin Invest*. 2011;41:1361–6.
23. Kajiya M, Giro G, Taubman MA, Han X, Mayer MPA, Kawai T. Role of periodontal pathogenic bacteria in RANKL-mediated bone destruction in periodontal disease. *J Oral Microbiol*. 2010;2(2010):1–16.
24. Kresnoadi U, Rahmania PN, Caesar HU, Djulaeha E, Agustono B, Dimas M, et al. The role of the combination of *Moringa oleifera* leaf extract and demineralized freeze - dried bovine bone xenograft (xenograft) as tooth extraction socket preservation materials on osteocalcin and transforming growth factor - beta 1 expressions in alveo. *J Indian Prosthodont Soc*. 2019;19(2).
25. Djais AI, Oktawati S, Thahir H, Hatta M, Sukmana BI, Dewi N, Huldani, Inayah Y, Widodo, Riewpassa IE, Achmad H, Dewang D. Effect of the Combination of Demineralization Freeze Dried Dentin Matrix (DFDDM) and *Moringa Oleifera* Lam on Nuclear Factor Kapa B as a Marker of Bone. *Systematic Reviews in Pharmacy*. 2020; 11(4): 515-522. doi: [10.31838/srp.2020.4.78](https://doi.org/10.31838/srp.2020.4.78)
26. Djais AI, Oktawati S, Thahir H, Hatta M, Sukmana BI, Dewi N, Huldani, Inayah Y, Widodo, Riewpassa IE, Achmad H, Dewang D. The Effect of the Combination

- of Demineralization Freeze Dried Dentin Matrix (DFDDM) and Moringa oleifera Lam to increase Fibroblas and Osteoblas cell in Alveolar Bone after Caviacobaya's Tooth Extraction. Systematic Reviews in Pharmacy. 2020; 11(4): 523-530. doi: [10.31838/srp.2020.4.79](https://doi.org/10.31838/srp.2020.4.79)
27. Achmad H, Oktawati S, Adam AM, Pasiga B, Sjahril R, Azizah A, Sukmana BI, Huldani, Siswanto H, Neormansyah I. Granulicatella Adiacens Bacteria Isolation from Perodontitital Patients with Polymerase Chain Reaction Techniques. Systematic Reviews in Pharmacy. 2020; 11(4): 394-400. doi: [10.31838/srp.2020.4.59](https://doi.org/10.31838/srp.2020.4.59)
28. Huldani, Pattelongi I, Massi MN, Idris I, Bukhari A, Widodo ADW, Achmad H. Research Reviews on Effect of Exercise on DAMP's, HMGB1, Proinflammatory Cytokines and Leukocytes. Systematic Reviews in Pharmacy. 2020; 11(4): 306-312. doi: [10.31838/srp.2020.4.44](https://doi.org/10.31838/srp.2020.4.44)
29. Achmad H, Thahir H, Rieuwpassa I, Mardiana AA, Oktawati S, Samad R, Djais AI, Gani A, Singgih MF, Madjid F, Admy SC. The Effectiveness of Channa striata Extract Antimicrobial Effect on Periopathogen Bacteria (Porphyromonas gingivalis and Aggregatibacter actinomycetemcomitans).