

Estimate Toxic Effect Of Silica Nanoparticles On Kidney, Liver And Lung Function Of Male Albino Rats

Leena Adeeb Mehdi¹, Alaa Mohammad Hasson Al-Husseini²

¹University of Kufa, Faculty of Agriculture, Department Animal Production, Iraq

²University of Al-Qadisiyah, College of Science, Department Of Biology, Iraq

*Corresponding Author: leena.alweli@uokufa.edu.iq

ABSTRACT

The current study was carried out in the animal house of faculty of science/Kufa university on thirty male albino rats to determine the toxic effect of nano silica on some organs, kidney, lungs and liver in the male adult rats that treated with two concentrations (100,150)mg/kg of silica nanoparticles for 30 days. the kidney and liver functions were determined by biochemical markers (AST, ALT, Urea and Creatinine), and histopathological analysis was performed to all studied organs. the results showed a significant elevation in ALT, AST Urea and Creatinine levels in serum of male rats. the histopathological results showed severe damage in the tissue of kidney, liver and lungs especially at high concentration 150mg/kg. It caused necrosis, dilation in renal tubules and inflammation of hepatocytes, also, there was metaplasia in mucous and hypertrophy in lung tissue, these findings as a response to administration orally of silica nanoparticles.

Keywords: silica nanoparticles, kidney, liver, lung, liver enzymes, urea, creatinine

Correspondence:

Leena Adeeb Mehdi

University of Kufa, Faculty of Agriculture, Department Animal Production, Iraq

*Corresponding author: Leena Adeeb Mehdi email-address:

leena.alweli@uokufa.edu.iq

INTRODUCTION

Silica nanoparticles are used in various fields as additives to food, cosmetics and drugs. Furthermore, widely used of silica nanoparticles in medicine and pharmacy caused increased human exposure to nanoparticles at different types and sizes [1]. Although, silica nanoparticles are made of non-toxic materials, their potential interactions with several biological materials in several ways is accumulating, some materials become toxic when they are present in nanometer size, many studies revealed that silica nanoparticles induced reactive oxygen species in all cells of pulmonary system, lung epithelial cells and pleural mesothelium [2]. In addition, most studies demonstrated that dermal exposure for 3 days to silica nanoparticles caused penetration the skin and localization silica nanoparticles at lymph nodes, then dermal exposure of silica nanoparticles for 30 days resulted in absorption into the brain and liver [3]. Currently, more exposure to nanomaterial caused toxicity for many organs in the human body, silica nanoparticles exposure result from oxidative injury, inflammatory reaction following cell membrane disruption, genotoxic impact, necrosis and death of cells [4]. The toxic effect of silica nanoparticles resulted from its small size that leads to exponential raise the surface area, also, its shape has a crucial role in the toxicity of nanoparticles especially when interacting with the biological system [5]. Inhalation of nano silica causes respiratory harmful raises the heart disease and increase the levels of fibrinogen and the concentration of red blood cells [6]. Treated with nano silica also results in production of hydroxyl radical [7] and caused harmful to liver [8]. There are many methods of toxicity has been presented contain DNA harmful and accumulation of protein in cell [9], metabolomics [10] oxidative pressure and apoptosis. In addition to its effect on the expression of some fertility genes, which reflects negatively on the efficiency of the reproductive system [11], as tissue changes in the testes and epididymis of rats treated with silica were observed [12].

The studied about the toxic impact of nano silica on some organs of male rats like lung, kidney and liver is little, thus, the present study was carried out to demonstrated the

toxicity of exposure to silica nanoparticles solution after oral administration of male rats.

MATERIALS AND METHODS

Preparation of silica nanoparticles:

For synthesis of SiO₂, the precursor (Na₂SiO₃) was diluted with distilled water (with ratio 1:2) for 4 hours and then 1 M of hydrochloric acid was added and shaken at room temperature (RT) till pH changed from pH 12 to pH 7. The white powder was obtained by filtration then washed with distilled water to neutralize the acid and dried at a temperature of 60°C for about 12 h [13].

Laboratory animals

Thirty male rats were housed to a 12 light /dark cycle at the animal house of the college of science/ University of Kufa and environmental condition was maintained at a constant temperature of (22-25)°C, water and autoclaved food were provided ad libitum. the rat weight between (250-300) gm.

Experimental Design

The present study included an effect of oral administration silica nanoparticles at two different concentrations for 30 days on hepatorenal functional efficiency and lungs. (30) male rats were randomly divided into three identical groups; (figure -1), each group involved (10) animals as follow: male rats were divided into three groups:

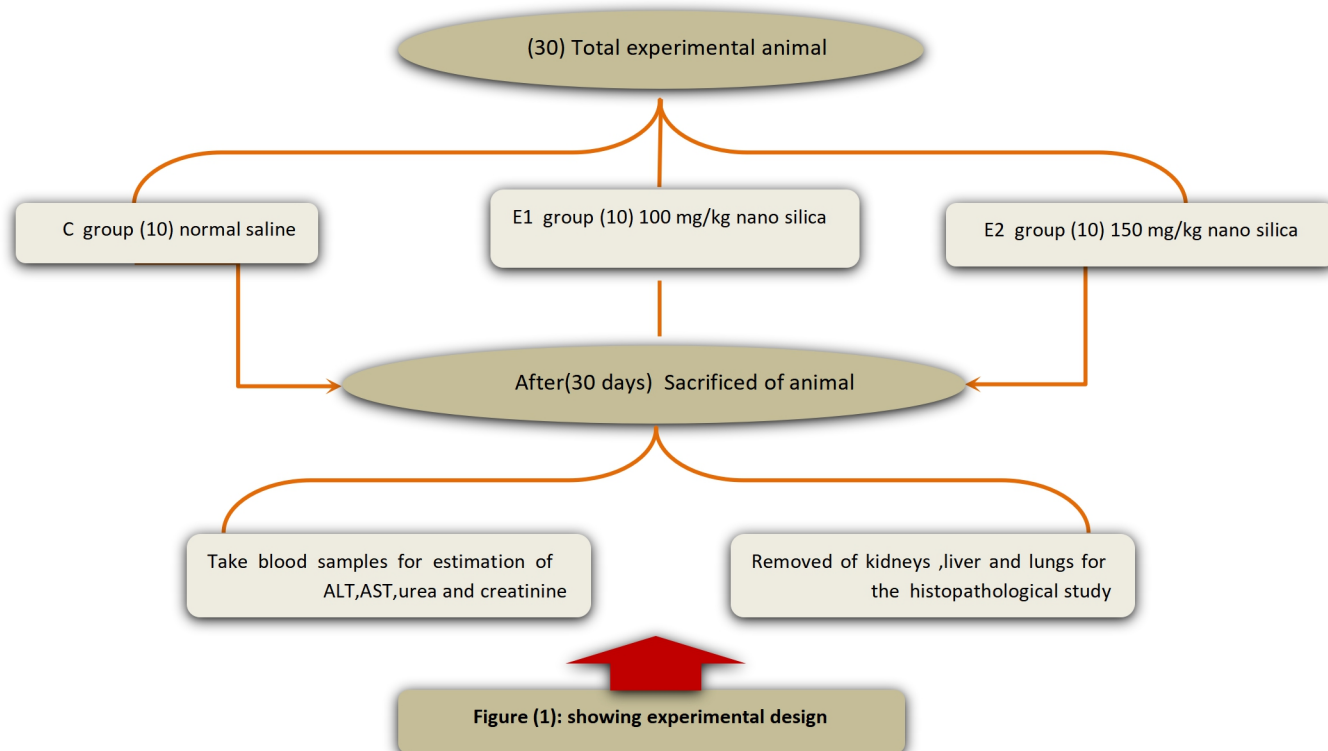
First experimental group (E1): involved (10) male rats received orally (100)mg/kg silica nanoparticles solution by gavage technique throughout the trial period.

Second experimental group (E2): involved (10) male rats received orally (150)mg/kg silica nanoparticles solution by gavage technique throughout the trial period.

Control group (C): involved (10) male rats received normal saline orally by gavage technique throughout the trial period.

at the end of the experiment, the blood samples collected to estimation levels of the ALT, AST, creatinine and urea. kidney, liver and lung were removed from all animals and they fixed in 10% formalin for histopathological examination

Estimate Toxic Effect Of Silica Nanoparticles On Kidney, Liver And Lung Function Of Male Albino Rats



Serological study

the concentrations of liver enzymes ALT and AST in serum were estimated by using the ELISA technique. Rat ALT ELISA Kit (ab234579) with 15.2 ng/ml sensitivity. and Rat AST ELISA Kit (Aspartate Aminotransferase) (ab263883) with 42.4 pg/ml sensitivity. They were Made by Abcam company. According technical instructions that described in Kit's producer were followed.

To detection of the levels, urea and creatinine in serum used colorimetric method. The reagents manufactured by Randox were used [14].

Histopathology study

The tissue preparation steps were undertaken for histopathological examination depending on the method of Steven and Bancroft [15].

Statistical analysis:

The quantitative data were expressed as mean \pm standard error (SE) for measurements. Statistical analyses were performed by using one- way analysis of variance depending on the Graphpad Prism 7 program. Statistical significance was defined as a *P*-value of $P < 0.05$, $P < 0.001$ and $P < 0.0001$.

RESULTS

Data present in histograms (figure 2) shows the levels of ALT Alanine transaminase, AST Aspartate transaminase, creatinine and urea in the rats that treated with silica nanoparticles in E1 and E2 at concentrations(100 and 150) mg/kg respectively, as compared with control. The differences in the levels of ALT and AST consider one of the biomarkers that indicated the Functional performance of the liver in this study, serum ALT and AST levels (figure 2 in A and B) recorded a significant increase ($p < 0.0001$) in E2 in comparison with the control group and E1 group ($p < 0.001$), while there were no significant differences ($p > 0.05$) between the control group and E1 group. On the other hand that treated with nano silica solution at 150 mg/kg in E2 group caused a significant increase of creatinine levels in the serum compared with the control group ($p < 0.001$) and E1 group ($p < 0.05$) as

shown in (figure 2C). while the treated with silica nanoparticles at concentration 100 mg/kg no effects on the creatinine levels in comparison with the control group ($p > 0.05$). Results of effects of nano silica on the urea levels in serum revealed there were high significant different at two concentration (100 and 150) mg/kg in E1 at level p -value < 0.001 and E2 at level p -value < 0.0001 in comparison with control groups (figure 2D).

Histological results show no obvious changes in kidney tissue of control group (figure 3A), while in E1 group that treated with 100 mg/kg of silica nanoparticles (figure 3B) there was an infiltration of lymphocyte cells, dilation in renal tubules also, vacuolation and necrosis in some renal tubules lining epithelium and congestions the others. In addition to infiltration of inflammatory mononuclear cells in the interstitial tissue. Treated with 150 mg/kg of silica nanoparticles is showing dilation and vascular congestion in the interstitial tissue and infiltration of inflammatory mononuclear cells has been observed with dilation in some renal tubules (figure 3C).

the liver tissues of control group presented the normal histological structure of hepatocytes that surround central vein (figure 4A), group E1 that treated with 100mg/kg of silica nanoparticles (figure 4B) showed mild vacuolar degeneration in hepatocytes and congestion of central vein with a proliferation of kuppfer cells. In the group treated with 150 mg/kg silica nanoparticles is showing congestion in hepatic sinusoids with degeneration and necrosis of hepatocytes (figure 4C). histological section of the lung (figure 5) showed normal histological lung structure of rats in the control group (A), In E1 group that treated with 100mg/kg of silica nanoparticles investigated wall thickening, subepithelial fibrosis, mucous metaplasia, deposition of extracellular matrix in the subepithelial layer, myofibroblast hyperplasia, bronchial smooth muscle hyperplasia and hypertrophy (figure 5B). While in E2 group treated with 150mg/kg of silica nanoparticles, there was severe inflammation and inflammatory cells (figure 5C).

Estimate Toxic Effect Of Silica Nanoparticles On Kidney, Liver And Lung Function Of Male Albino Rats

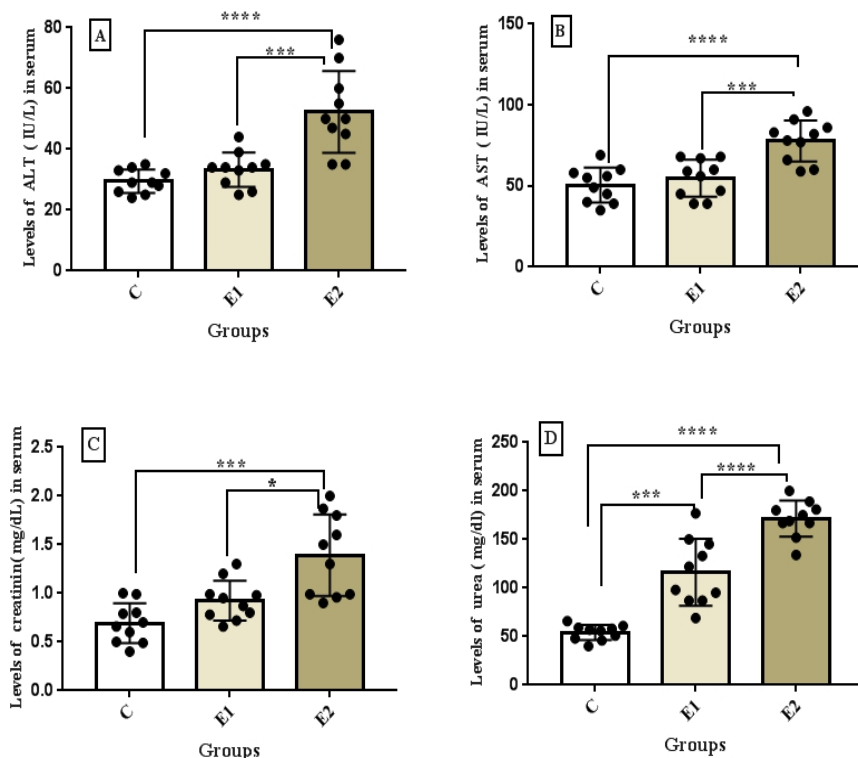


Figure (2):effects of nanosilica on the liver and kidney functions of the male rat (A) ALT in serum (B) AST in serum (C) creatinine in serum (D) urea in serum .Each group (n=10).Groups :(C) represent control ,(E1)represent first experimental group and (E2) second experimental group . Values represent means ±standard error . p-values at levels (<0.05* , P<0.001*** and P<0.0001****)

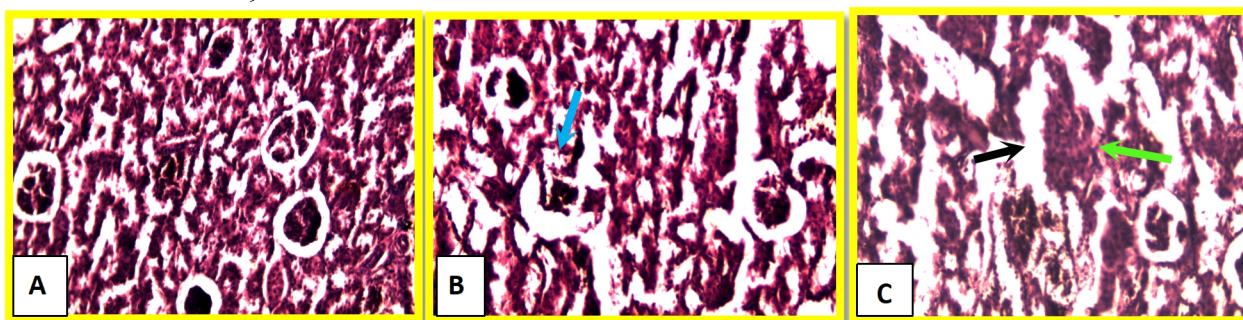
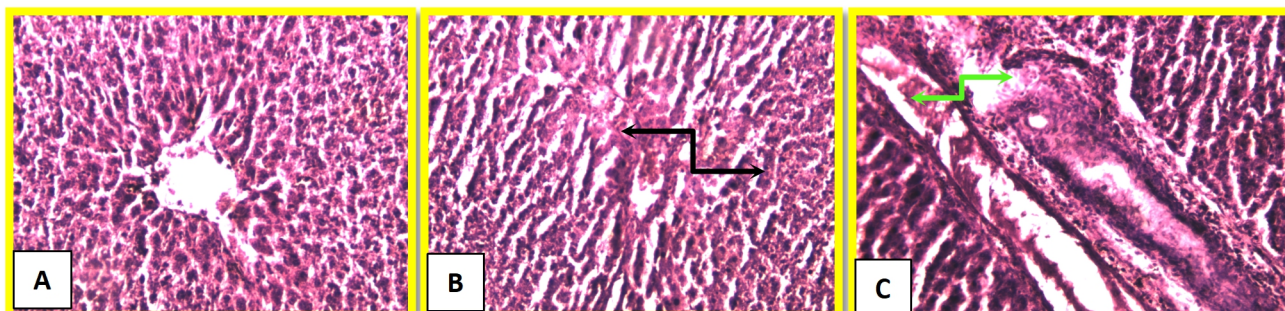


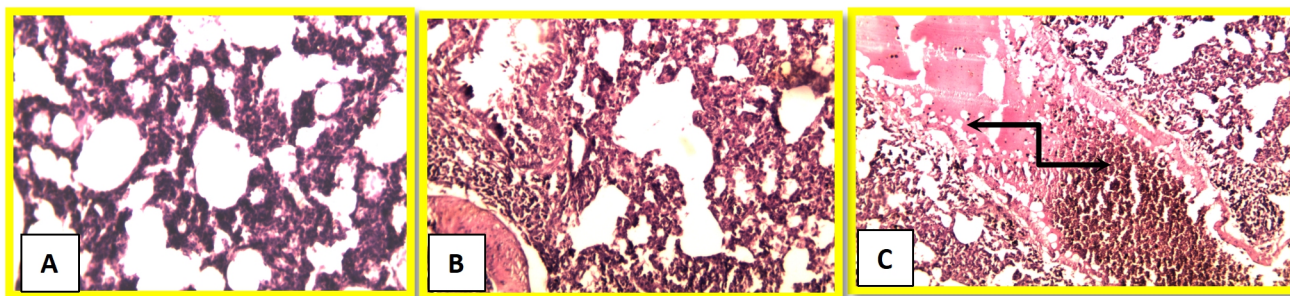
Figure (3) effect of nanosilica on the kidney tissue of the male rats. (A) indicate to control group,(B) indicate to (E1)first experimental group and (C) indicate to (E2) second experimental group, it showed infiltration of

lymphocyte cells(blue arrow), dilation in renal tubules (black arrow), necrosis in some renal cells and congestions the others(green arrow). H&E stain 100X.



Figure(4) effect of nanosilica on liver tissue of male rat: .(A) indicate to control group,(B) indicate to (E1)first experimental group and (C) indicate to (E2) second experimental group, it showed necrosis and degeneration

in hepatocytes(black arrows), dilation and congestions in sinusoids of liver tissue that treated with silica nanoparticles (green arrows). H&E stain 100X.



Figure(5) effect of nanosilica on lung tissue of male rats: (A) indicate to control group ,(B) indicate to (E1)first experimental group and (C) indicate to (E2) second experimental group, it showed congestion in lung tissue with infiltration in inflammatory cells and degeneration of epithelial lung tissue (black arrow). H&E stain 100X.

DISCUSSION

Many studies on the laboratory animal have proved that silica nanoparticles resulting in multiple organs damages which lead to disorders such as fibrosis of lung and pleural effusion. Other studies show that inhaled silica nanoparticles not only caused damage of lungs but also, liver, kidney and heart [16]. most essential organs for detoxification is kidney, liver and lungs, in present study we confirmed that silica nanoparticles can induce kidney and liver injury especially at high concentrations 150 mg/kg as compared with control, while there was an increment in creatinine and urea levels because of the toxic effect of silica nanoparticles which caused oxidative stress [17]. Oxidative stress is the result of an imbalance in cellular biosystem between the production of free radicals and cellular defense mechanisms. Increases in free radicals or decreases in anti-oxidant substances

Can impair the balance between oxidizing agents and anti oxidants. Oxidative stress can cause a variety of biochemical reactions that are potentially harmful [18]. Nanoparticles have been shown to generate reactive oxygen species (ROS) by pro-oxidant functional groups, active redox cycling and particle cell interactions [19]. Reactive oxygen species constitute a pool of oxidative species including superoxide anion, hydroxyl radical, hydrogen peroxide, singlet oxygen. The antioxidant defence mechanism is very important in response to reactive oxygen species toxicity. SOD superoxide dismutase is the first line of the defence mechanism and scavenges superoxide radicals. They are responsible for the conversion of H₂O₂ into H₂O and molecular O₂. The decomposition product of the polyunsaturated fatty acids is produced naturally as a result of lipid peroxidation and is often used as an indicator of oxidative damage at the cellular level[20].

Earlier studies have shown that the toxicological induction of NPS Effects of various organs, particularly on the Kidneys, liver, spleen and lungs [21].in the present study, the activity of the liver enzymes (AST and ALT) were significantly elevated in male rats treated at 150mg/kg nano silica. This finding shows hepatic damage which changes the hepatocytes Permeability of the membrane

That triggers enzyme leakage from those cells. In accordance with this finding, some investigators have reported an increase of AST and ALT activities in

serum following silica nanoparticles administration [22]. Some studies have indicated that the liver is known as a major nano Silica because it is a reticuloendothelial system organ [23]; also, our data shows elevations in the levels of Creatinine and urea in serum in rats that administrated with silica nanoparticles .this indicate to reductions in the rate of glomerular filtration [24].

In the current study, the alteration in the liver section of male rat that administrated with silica nanoparticles in concentration 100mg/kg showed mild degenerative changes in some hepatocytes and slight congestion of blood vessels, on another hand, the liver tissue of E2 at level 150 mg/kg of nanosilica showed severe histological changes, there was focal necrosis and severe vacuolar degradation in the hepatocytes. Also, Kupffer cells have demonstrated mild proliferation and slight congestion in the Hepatic sinusoids these findings associated with those of indicators of liver's function represented by enzymes AST and ALT concentrations were increment in the rats that treated with silica nanoparticles , in addition to, infiltration of inflammatory cell and hepatocytes adipose degeneration of the liver's tissues [25].Some hepatocytes may have hepatic vacuolation, karyolysis,and pycnotic nuclei due to cell injury. [26].

Kidneys rats of the group treated with 100 mg/kg of silica nanoparticles indicated slight degenerative the in E2 group which treated with 150 mg/kg of silica nanoparticles glomerular tuft uncovered blockage and decay, notwithstanding vacuoles of glomerular coating endothelium. Some renal corpuscles uncovered corruption of kidney tuft. Interstitial tissue indicated the invasion of mononuclear fiery cells. There was coagulate rot of an impressive number of renal cylindrical covering epithelium. these results greed with [27] that noticed the damage in kidney tissue of male rats, there were cell swelling and necrosis treated with silica nanoparticles[28].

The histological changes of lung evidence various degree of inflammation caused by toxicity of silica nanoparticles compared with the control group, there were Wall thickening, sub epithelial fibrosis, mucous metaplasia, deposition of extracellular matrix in the sub epithelial layer, myo fibroblast hyperplasia, bronchial smooth muscle hyperplasia and hypertrophy [27].

However, high concentration of silica nanoparticles 150mg/kg caused severe changes in lung tissue of male rats, cell necrosis and aggregation large number of nanoparticles in the airway caused obstruct [29].

Nanoparticles are similar in size to biological molecules such as proteins, DNA and viruses so they are likely to Penetrate through the skin barrier pulmonary and blood barrier and penetrate the body through simple diffusion and penetration. These silica nanoparticles are

Estimate Toxic Effect Of Silica Nanoparticles On Kidney, Liver And Lung Function Of Male Albino Rats

Prone to penetration through membranous pores and enter into the cells or cytoplasmic organelles such as mitochondria, lysosomes, endoplasmic reticulum, lysosomes and the nuclei to in combination with biological macromolecules or catalytic reactions that occur simultaneously [30] The normal biological macromolecules and three-dimensional structure of the biological membrane are thus changed, causing the loss of some major activity of hormones and enzymes [31].

REFERENCES

1. Bahadar H, Maqbool F, Niaz K, Abdollahi M. Toxicity of nanoparticles and an overview of current experimental models. *Iran Biomed J.* 2016;20(1):1-11.
2. Berg JM, Romoser AA, Figueroa DE, Spencer West C, Sayes CM. Comparative cytological responses of lung epithelial and pleural mesothelial cells following in vitro exposure to nanoscale SiO₂. *Toxicol In Vitro.* 2013;27(1):24-33.
3. Hirai T, Yoshikawa T, Nabeshi H, et al. Dermal absorption of amorphous nano silica particles after topical exposure for three days. *Pharmazie.* 2012;67(8):742-743.
4. Gong C, Tao G, Yang L et al (2012) The role of reactive oxygen species in silicon dioxide nanoparticle-induced cytotoxicity and DNA damage in HaCaT cells. *Mol Biol Rep* 39:4915-4925.
5. Rahman IA, Padavettan V. Synthesis of silica nanoparticles by sol-gel: size-dependent properties, surface modification, and applications in silica-polymer nanocomposites—a review. *J Nanomater.* 2012; Article ID 132424.
6. Athinarayanan J, Periasamy VS, Alsaif MA Al-Warthan AA, Alshatwi AA. Presence of nanosilica (E551) in commercial food products: TNF-mediated oxidative stress and altered cell cycle progression in human lung fibroblast cells. *Cell Biol Toxicol.* 2014; 30:89-100.
7. Nabeshi HT, Yoshikawa K, Matsuyama Y, Nakazato S, Tochigi S .et al (2011) Amorphous nanosilica induce endocytosis-dependent ROS generation and DNA damage in human keratinocytes. *Part Fibre Toxicol* 8:1.
8. Nemmar A, Yuvaraju P, Beegam S, Yasin J, Kazzam EE, Ali BH. Oxidative stress, inflammation, and DNA damage in multiple organs of mice acutely exposed to amorphous silica nanoparticles. *Int J Nanomed* 2016;11:919-928.
9. Balli E, Comelekoglu U, Yalin S, Battal D, Ocakoglu K, Sogut F, Yaman S, Turkseven CH, Eroglu P, Karagul I, Goney G, Yildirimcan S, Aktas A. Toxic effects of silica nanoparticles on heart: electrophysiological, biochemical, histological and genotoxic study. *Fres Environ Bull.* 2016; 25(2): 612-622.
10. Battal D, Çelik A, Güler G, Aktaş A, Yildirimcan S, Ocakoglu K, Çömelekoğlu Ü. Drug Chem Toxicol. SiO₂ Nanoparticle-induced size-dependent genotoxicity - an in vitro study using sister chromatid exchange, micronucleus and comet assay. *Drug Chem Toxicol.* 2015;38(2):196-204.
11. Allawi L. A. H., Mohammad H. A. A.Effect of Silica Nanoparticles on level Cyp19a1and Cyp17a1genes in Male Rats.*Journal of Physics: Conference Series*, 2019, 1294(6), 062053.
12. Al-Husseini, A.M.H., Al-khazay, H.A.L. Effects of silica nanoparticles on some indicators of fertility and histological changes in male rats. *Journal of Global Pharma Technology.*201810(5), pp. 79-87.
13. Parveen A, Rizvi SH, Sushma, Mahdi F, Ahmad I, Singh PP, Mahdi AA. Intranasal exposure to silica nanoparticles induce alterations in pro-inflammatory environment of rat brain: involvement of oxidative stress. *Toxicol Ind Health.* 2017;33(2):119-132.
14. Bartels,H. and Bohmer,M. Serum creatinine determination without protein precipitation *Clin Chim Acta*, 1972;37: 193-197.
15. Bancroft, J.D and Stevens, A. Theory and practice of histological techniques. Churchill living stone, New York.1982; 76(2): 351 - 356.
16. Zande M, Vandebriel R, Groot M, et al. Subchronic toxicity study in mice orally exposed to nanostructured silica. *Part Fibre Toxicol.*2014; 11: 1- 19.
17. Sies H. Oxidative stress: a concept in redox biology and medicine. *Redox Biol.* 2015;4:180-183
18. Kim JH, Kim CS, Ignacio RM, Kim DH, Sajo ME, Maeng EH, Qi XF, Park SE, Kim YR, Kim MK, Lee KJ, Kim SK. Immunotoxicity of silicon dioxide nanoparticles with different sizes and electrostatic charge. *Int J Nanomed.* 2014; 9(Suppl 2):183-193.
19. Almansour M, Alarifi S, Jarrar B. In vivo investigation on the chronic hepatotoxicity induced by intraperitoneal administration of 10-nm silicon dioxide nanoparticles. *Int J Nanomedicine.* 2018; 13:2685-2696.
20. I. M. Joni, L. Nulhakim, M. Vanitha and C. Panatarani, "Characteristics of crystalline silica (SiO₂) particles prepared by simple solution method using sodium silicate (Na₂SiO₃) precursor," in 3rd Padjadjaran International Physics Symposium, *Journal of Physics: Conference Series* 1080, edited by Risidiana et al. (IOP Publishing, Bristol, 2018), pp. 012006:1-6.
21. Wang J, Zhou G, Chen C et al (2007) Acute toxicity and biodistribution of different-sized titanium dioxide particles in mice after oral administration. *Toxicol Lett* 168:176-185
22. Fu C, Liu T, Tang F, Chen D, Li LL, Liu HY, Li XM(2012) Acute toxicity and oxidative damage induced by silica nanoparticle in vivo. *Chin Sci Bull* 57:2525-2532
23. Lee S, Kim M, Lee D, Kwon TK, Khang D, Yun H, Kim S (2013) The comparative immunotoxicity of mesoporous silica nanoparticles and colloidal silica nanoparticles in mice. *Int J Nanomedicine* 8:147-158.
24. Naziroglu M, Karaoglu A, Aksoy AO (2004) Selenium and higher dose vitamin E administration protects cisplatin induced oxidative damage to renal, liver, lens tissues in rats. *Toxicology* 195:221-230.
25. Fattin SM, Abd ElSalam NF, Bahaa N, Baher W .Effect of silica oxide nanoparticles on liver of adult male albino rat. Light and electron microscopic study. *Egypt J Histol.* 2017; 40(3):345-361.
26. Hassankhani R, Esmaeillou M, Tehrani AA et al (2014) In vivo toxicity of orally administrated silicon dioxide nanoparticles in healthy adult mice. *Environ Sci Pollut Res.*
27. Lai LC,Qian X,Ming CW, Jin F,Na Na S, Peng ZX, Ning LY,Hui Y et al . Subchronic oral toxicity of silica nanoparticles and silica microparticles in rats. *Biomed Environ Sci.* 2018; 31(3):197-207.
28. Manke A, Wang L, Rojanasakul Y. Mechanisms of nanoparticle-induced oxidative stress and toxicity. *BioMed Res Int.* 2013; 2013:1-15.

Estimate Toxic Effect Of Silica Nanoparticles On Kidney, Liver And Lung Function Of Male Albino Rats

29. Naziroglu M, Karaoglu A, Aksoy AO. Selenium and higher dose vitamin E administration protects cisplatin induced oxidative damage to renal, liver, lens tissues in rats. *Toxicology*.2004; 195:221-230.
30. Passagne I, Morille M, Rousset M, Pujalté I, L'azou B. Implication of oxidative stress in size-dependent toxicity of silica nanoparticles in kidney cells. *Toxicology*. 2012;299(2-3):112-124.
31. Su Y, Xu JY, Shen P, Li J, Wang L, et al. Cellular uptake and cytotoxic evaluation of fullerenol in different cell lines. *Toxicology*.2010; 269(2-3): 155-159.