

The diagnostic value of AFP, AFP L3 and PIVKA II in hepatocellular carcinoma outcome of cirrhosis of the liver HBV and HCV etiology

Dr. Ayad yas khudair

Al-Hussein Teaching Hospital, Samawah, Al-Muthanna, Iraq M.B.Ch.B ,F.I.C.M.S,C.A.B.M.S(surgery)

ABSTRACT

Hepatocellular carcinoma (HCC) is the third largest cause of death among all cancer cases in the world. Moreover, in most cases, it develops against the background of viral hepatitis of the liver. It should be noted, and the fact that the detection of the later stages of the forecast it usually unfavorable. This study focuses on AFP, AFP L3, and PIVKA II as oncological markers of HCC in patients with chronic viral hepatitis. It was found that the use of the combination of PIVKA II and AFP increases the sensitivity by 16.6% compared with the use of AFP alone, which is comparable with the results of all three-tumor markers.

Keywords: HCC, cirrhosis, HBV, HCV, HDV, AFP, AFP L3, PIVKA II, screening.

Correspondence:

Dr. Ayad yas khudair
Al-Hussein Teaching Hospital, Samawah, Al-Muthanna, Iraq
M.B.Ch.B ,F.I.C.M.S,C.A.B.M.S(surgery)

INTRODUCTION

According to GLOBOCAN (oncology database) for 2018, primary liver cancer is the sixth most common and fourth in the structure of oncological mortality: annually, primary liver cancer accounts for about 841,000 new cases and 782,000 deaths [1]. In the Republic of Uzbekistan, in the structure of oncological morbidity for 2018, HCC takes the seventh place, with an incidence rate of 2.6 per 100 thousand people. At the same time, stage III and stage IV of the HCC account for 63.8% of all newly detected cases, while stage I accounts for no more than 2%. It should be noted that HCC in 80-90% of cases develops against cirrhosis of the liver [15]. This is primarily because cirrhosis is the result of prolonged liver damage. In addition, in 20% of cases, HCC is diagnosed with newly diagnosed cirrhosis. Most often, HCC develops against HBV and HCV, which are detected in 80-90% of patients with HCC against cirrhosis. According to global data, HBV accounts for about 50% of all cases of HCC. It should be noted that in chronic HBV infection, the risk of developing HCC increases by 15-20 times. Moreover, in 70-90% of cases, HCC develops after cirrhosis due to chronic hepatitis B [11]. At the same time, with chronic HCV infection, the risk of developing HCC is increased by 17 times [3]. And against the background of cirrhosis of the liver of HCV etiology, the risk of HCC increases annually by 1-4% [5].

The following findings are sufficient to establish the diagnosis of HCC according to practical recommendations of the World Gastroenterological Organization: the classic picture with one of the visual research methods, for example, a large and / or multifocal formation in the liver, as well as an increased level of AFP (alpha-fetoprotein), against the background of liver disease at the stage of cirrhosis. The definition of a tumor on ultrasound is operator-dependent and not always reliable for cirrhosis. Despite the fact that AFP is an inexpensive biomarker, it has relative sensitivity [2], since it can be increased in chronic liver diseases, pregnancy, and genital tumors, with active hepatitis and cirrhosis [11]. In most cases (70-80%) at the time of diagnosis of HCC, the possibility of surgical treatment and liver transplantation has

already been missed and 3-year survival is reduced to 20-40% [16]. More specific for HCC is AFP L3. However, its determination is impossible with a low level of AFP and therefore not always acceptable. Currently, for the diagnosis of HCC, it is also recommended to use PIVKA II, also known as des-gamma-carboxy-prothrombin, whose level above 10 ng / ml speaks in favor of HCC [12]. PIVKA-II is a pathological inactive prothrombin with insufficient carboxylation due to a post-translational defect of the prothrombin precursor in primary liver cancer cells [7].

MATERIAL AND METHODS

All subjects were divided into three groups. The first group included patients with a diagnosis of HCC associated with liver cirrhosis, HCV, HBV, HDV etiology. The selection criteria for the patients were the mandatory presence of volume formation on ultrasound + CT / MRI with histological confirmation of the diagnosis, and markers of chronic viral hepatitis. The second group included patients with cirrhosis induced by HCV, HBV and HDV infection without HCC. The selection criteria for this group were the presence of viral hepatitis markers and the absence of volume formation on an ultrasound scan. The third group was composed of healthy volunteers. The study was conducted with the permission of the ethics committee of the Ministry of Health of the Republic of Uzbekistan. All subjects received written consent to take clinical material (blood) and publish the results. The diagnosis of cirrhosis was classified according to the Child-Pugh [14] and patients with HCC on the background of cirrhosis furthermore classified according to the TNM classification used in our country [17]. In the sera studied, we determined the level of AFP, AFP L3 and PIVKA II by ELISA on a Biotek spectrophotometer. Measurements of tumor markers were carried out in the same samples taken from patients simultaneously. To determine the level of AFP, the "AFP-IFA-BEST" kit of Vector Best (Russia) was used. To determine the level of AFP L3, we used the ELISA Kit Alpha-Fetoprotein Lens Culinaris Agglutinin (aAFP L3). To determine the level of PIVKA II, we used ELISA KIT Human Protein Vitamin K

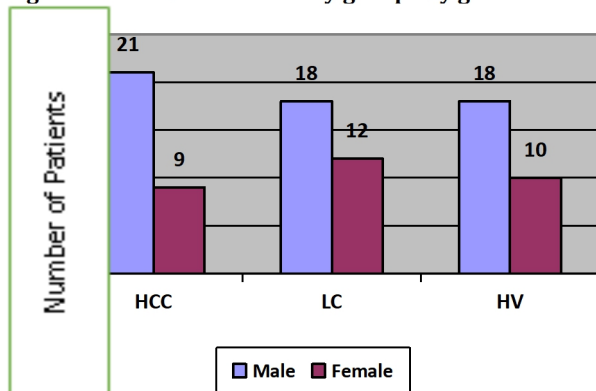
The diagnostic value of AFP, AFP L3 and PIVKA II in hepatocellular carcinoma outcome of cirrhosis of the liver HBV and HCV etiology

Absence or Antagonist-II (PIVKA II) from Cusabio (USA). The analysis was carried out according to the instructions of manufacturers.

RESEARCH RESULTS

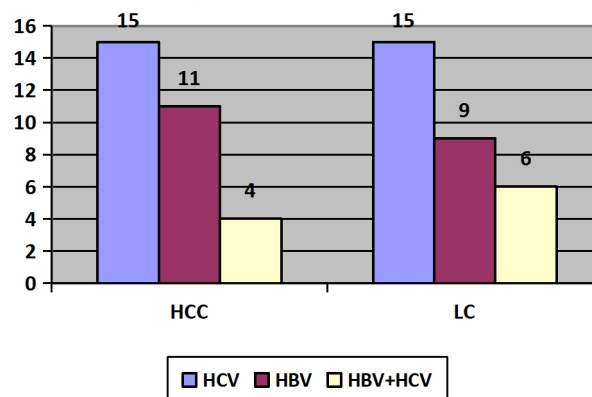
A total of 88 people were examined. Of these, 30 patients with HCC against cirrhosis of the liver HBV, HDV and HCV etiology, 30 patients with cirrhosis of the liver HBV, HDV and HCV etiology without HCC and 28 healthy volunteers. In the group of patients with HCC, the average age was 58.0 ± 5.1 years, in the group of patients with CP without HCC 56.9 ± 4.95 years and in the group of healthy volunteers 56.0 ± 5.5 years. In all three groups, men predominated by gender (Figure 1).

Figure 1. Distribution of study groups by gender



All patients with HCC and cirrhosis were tested for viral hepatitis markers, while viral hepatitis markers were negative in the volunteer group (Figure 2).

Figure 2. Distribution of patients with HCC and cirrhosis by etiological criterion



In the group with HCC, the level of AFP was within 203.9 ± 180.5 ng / ml, was higher than in the group with cirrhosis without HCC, the level of AFP in which was 19.94 ± 13.4 ng / ml. Also, when comparing the level of AFP in the control group, the level of which was within 2.58 ± 1.5 ng / ml, the level of AFP in the group with HCC was significantly higher ($p < 0.001$). However, in 9 patients with HCC, the AFP level was below 10 ng / ml. And in 11 out of 30 patients with cirrhosis without HCC and in 1 healthy volunteer, the AFP level was higher than 10 ng / ml, that is, above the upper limit of normal.

Tumor characteristics	Number of patients	AFP above 20ng/mL	AFP-L3(> 10 %)	PIVKA-II(>10 ng/mL)	AFP, AFP-L3 and PIVKA-II combined
Tumor Stage(TNM)					
I	0 (0%)	-	-	-	-
II	2(6,6%)	2	2	2	2
III	27(90,1%)	19	16	21	24
IV	1(3,3%)	0	0	0	0
Tumor size					
< 2 cm	0(0%)	0	0	0	0
2-5 cm	3(9,9%)	3	3	3	3
> 5 cm	27 (90,1%)	18	14	20	23
Tumor number					
Single	20(76,7%)	12	8	14	19
multiple	10(33,3%)	9	9	9	7

In the group of patients with HCC AFP L3 exceeded 10% of the main AFP in 18 out of 30 patients, while in the group of patients with cirrhosis in the outcome of viral hepatitis without HCC and in the group of healthy volunteers, it was within the threshold value.

In the group with HCC, the level of PIVKA II was within 14.59 ± 6.21 ng / ml and was significantly higher than in the group with cirrhosis without HCC, where the level of PIVKA II was 3.73 ± 1.75 ng / ml ($p < 0.001$). Also, when

comparing the level of PIVKA II in the control group (1.72 ± 1.06 ng / ml), the level of PIVKA II in the group with HCC was significantly higher ($p < 0.001$). We conducted an analysis of the results obtained by comparing tumor markers and their combinations with HCC (Table 1).

Table 1. The sensitivity of the studied markers depending on the characteristics of the tumor.

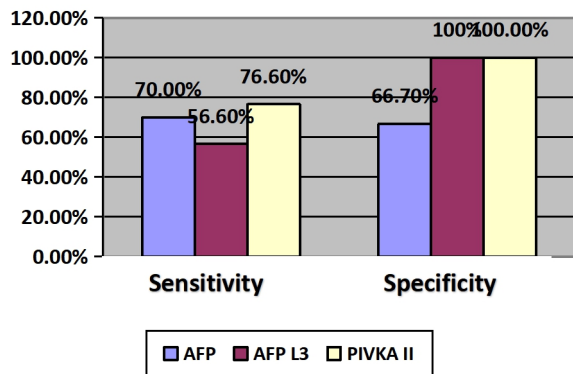
AFP- α -fetoprotein; AFP L3- α -fetoprotein L 3; PIVKA-II-Prothrombin induced by vitamin K absence-II; TNM-

The diagnostic value of AFP, AFP L3 and PIVKA II in hepatocellular carcinoma outcome of cirrhosis of the liver HBV and HCV etiology

Classification of Malignant Tumors; HCC- Hepatocellular carcinoma.

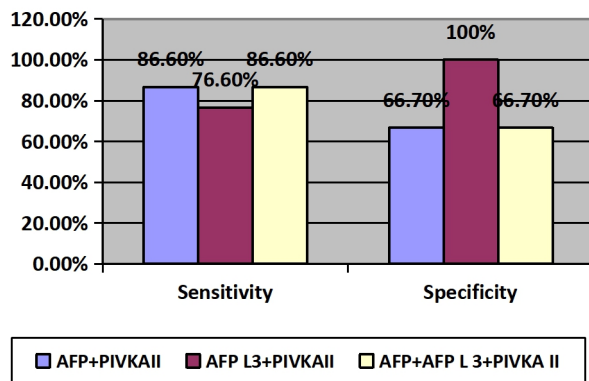
The results of our research showed that AFP sensitivity was 70%, specificity 66.7%, AFP L3-56.6% and 100%, and PIVKA II 76.6% and 100%, respectively (Figure 3).

Figure 3. Sensitivity and specificity of AFP, AFP L3 and PIVKA II.



In order to increase the effectiveness of the diagnosis of HCC, we compared the use of AFP + PIVKA II sensitivity, this combination was 86.6%, specificity 66.7%. The complex use of AFP L3 + PIVKA II showed a sensitivity of 76.6%, specificity of 100%. The determination of three tumor markers AFP + AFP L3 + PIVKA II showed a sensitivity of 86.6% and a specificity of 66.7% (Figure 4).

Figure 4. The sensitivity and specificity of combinations of tumor markers.



CONCLUSIONS

As is known, HCC up to 85% of cases develops against the background of chronic viral hepatitis. In this connection, it becomes necessary to diagnose HCC in patients with this pathology. Ultrasound is an operator-dependent method and it is not always possible to determine and differentiate small formations on it. More sensitive imaging methods, such as CT and MRI, are expensive and have a number of limitations and contraindications. In this connection, tumor markers are widely used as an additional diagnostic method. In this study, we evaluated the efficacy of AFP, AFP L3, and PIVKA II in patients with HCC and compared the levels of these tumor markers in patients with liver cirrhosis without HCC and in healthy volunteers.

Currently, AFP is broadly used in Uzbekistan as an oncological marker for HCC. However, in our study, AFP was increased in patients with hepatic cirrhosis of viral

etiology without HCC, as well as in healthy volunteers. The results of our studies showed that PIVKA-II was a better marker for diagnosis than AFP. These data are consistent with the work of other researchers [4, 10, 13]. The relatively low sensitivity of PIVKA-II, which is still higher than that of AFP, was balanced by high specificity (100%). It should be noted that the combination of PIVKA-II and AFP had a higher sensitivity compared to using only one of the biomarkers. These data confirm the data of other studies showing that PIVKA-II and AFP are mutually complementary tumor markers [6,9,18,19], and this is associated with different ways of their formation. The results of our study showed that the sensitivity of the combination of AFP and PIVKA II is identical to the use of all three markers (AFP + AFP L3 + PIVKA II). These data are consistent with the work of other researchers [4,10,13]. As for AFP L3, it should be noted that its level directly depends on the level of AFP. In this regard, the use of two AFP and PIVKA II markers is most optimal, while the use of AFP L3 can only be recommended if the AFP level is above 30 ng / ml, with a negative PIVKA II and a questionable ultrasound picture.

Despite the fact that AFP showed less sensitivity than PIVKA II. However, the combination of AFP + PIVKA II proved to be the most effective in the diagnosis of HCC, which is consistent with the data of Japanese authors [8]. Determination of the levels of AFP and PIVKA-II in blood serum is most suitable for routine diagnosis and screening of the population, since it requires a small amount of serum, simple enough and quick to complete. The study showed that the determination of tumor markers of HCC is a promising method for the diagnosis of early detection of primary liver cancer. The advantage of this method is low invasiveness, relative prostate and a high level of informational content (up to 86.6%). The introduction of this diagnostic method in everyday practice will significantly increase the early diagnosis of HCC in Uzbekistan, which, in turn, will reduce disability among this category of patients, improve survival and quality of life.

REFERENCES

- Bertino G., Ardiri A., Malaguarnera M., Malaguarnera G., Bertino N., Calvagno G.S. Hepatocellular carcinoma serum markers. *Semin Oncol.* 2012. 39(4). P. 410-433.
- Bray F, Ferlay J, Soerjomataram I, Siegel RL, Torre LA, Jemal A. Global cancer statistics 2018: GLOBOCAN estimates of incidence and mortality worldwide for 36 cancers in 185 countries. *CA Cancer J Clin*, Published online 12 September 2018
- Donato F, Tagger A., Gelatti U. et al. Alcohol and hepatocellular carcinoma: the effect of lifetime intake and hepatitis virus infections in men and women. *Am. J. Epidemiol.* 2002. Vol. 155. P. 323-331
- Durazo FA, Blatt LM, Corey WG, et al. Des-gamma-carboxyprothrombin, alpha-fetoprotein and AFP-L3 in patients with chronic hepatitis, cirrhosis and hepatocellular carcinoma. *J GastroenterolHepatol.* 2008.23. P.1541-8
- El-Serag H.B. Epidemiology of viral hepatitis and hepatocellular carcinoma. *Gastroenterology.* 2012. Vol. 142. P. 1264-1273
- Ertle JM, Heider D, Wichert M, et al. A combination of α -fetoprotein and des- γ -carboxy prothrombin is

*The diagnostic value of AFP, AFP L3 and PIVKA II in hepatocellular carcinoma
outcome of cirrhosis of the liver HBV and HCV etiology*

- superior in detection of hepatocellular carcinoma. *Digestion*. 2013.87.P.121–31
7. Gordeychuk I.N., Chirkov R.N., Babayan K.V.-Issues of early diagnosis of hepatocellular carcinoma. *Verkhnevolzhsky Medical Journal*. № 2
 8. Kokudo N, Hasegawa K, Akahane M, et al. Evidence-based Clinical Practice Guidelines for Hepatocellular Carcinoma: The Japan Society of Hepatology 2013 update (3rd JSH-HCC Guidelines). *Hepatol Res*. 2015.45. P.123–7
 9. Lok AS, Sterling RK, Everhart JE, et al. Des-gamma-carboxyprothrombin and alpha-fetoprotein as biomarkers for the early detection of hepatocellular carcinoma. *Gastroenterology*. 2010.138. P.493–502
 10. Marrero JA, Su GL, Wei W, et al. Des-gamma-carboxyprothrombin can differentiate hepatocellular carcinoma from nonmalignant chronic liver disease in american patients. *Hepatology*. 2003.37. P.1114–21
 11. Nguyen M.H., Garcia R.T., Simpson P.W., Wright T.L., Keeffe E.B. Racial differences in effectiveness of alpha-fetoprotein for diagnosis of hepatocellular carcinoma in hepatitis C virus cirrhosis. *Hepatology*. 2002. 36. P. 410–417
 12. Park SJ1, Jang JY, Jeong SW, Cho YK, Lee SH, Kim SG, Cha SW, Kim YS, Cho YD, Kim HS, Kim BS, Park S, Bang HI-Usefulness of AFP, AFP-L3, and PIVKA-II, and their combinations in diagnosing hepatocellular carcinoma. - *Medicine (Baltimore)*. 2017 Mar;96(11). e5811
 13. Poté N, Cauchy F, Albuquerque M, et al. Performance of PIVKA-II for early hepatocellular carcinoma diagnosis and prediction of microvascular invasion. *J Hepatol* 2015.62.P.848–54
 14. Pugh R.N., Murray-Lyon I.M., Dawson J.L. Transection of the oesophagus for bleeding oesophageal varices. *Br J Surg*. 1973. P. 646–649
 15. Sadridinov A.F., Tursunov E.A., Morphological analysis of the course of natural death of liver cells. *Journal of Biomedicine and Practice*, 2018, vol. 1, issue 4, pp. 28–34.
<http://dx.doi.org/10.26739/2181-9300-2018-4-5>
 16. S.R. Baimakov, S.Sh. Yunusov, S.E. Mamarajabov, Sh.S. Sh.Boltaev Kh.K.Rasulov. Hepatic echinococcosis by complicated mechanical jaundice (case report). *Journal of Biomedicine and Practice* 2019, vol. 2, issue 3, pp. 77-82. <http://10.26739/2181-9300-2019-3-8>
 17. Schegolev A.I., Mishnev O.D.-Oncomorphology of the liver. - Publishing house of the Russian State Medical University .2006. P. 251
 18. Sekacheva M., Bagmet N. Possibilities of treating inoperable liver cancer — *Volga Oncological Bulletin*-2011. 1 (5). P. 44-48
 19. Sobin L. H., Gospodarowicz M. K., Wittekind Ch. - International Union Against Cancer (UICC). *TNM Classification of Malignant Tumours*, 7th ed. / Eds. New York: Wiley-Blackwell. 2009
 20. Tateishi R, Yoshida H, Matsuyama Y, et al. Diagnostic accuracy of tumor markers for hepatocellular carcinoma.P. a systematic review. *HepatolInt* 2008.2.P.17–30
 21. Ullah MF, Aatif M. The footprints of cancer development: cancer biomarkers. *Cancer Treat Rev*.2009.35.P.193–200
 22. Wagner PD, Verma M, Srivastava S. Challenges for biomarkers in cancer detection. *Ann N Y Acad Sci*. 2004.1022.P.9–16
 23. Yoon YJ, Han KH, Kim DY. Role of serum prothrombin induced by vitamin K absence or antagonist-II in the early detection of hepatocellular carcinoma in patients with chronic hepatitis B virus infection. *Scand J Gastroenterol* 2009.44.P.861–6